West Virginia University Libraries
3 0802 101950455 7

Locked
Cage
RK
656
.S26
1898
HSL

DO NOT CIRCULATE

A TREATISE

ON

PLATELESS DENTURES

BY

C. A. SAMSIOE

PRACTISING DENTIST IN STOCKHOLM.

WITH 48 ILLUSTRATIONS.

TRANSLATED FROM THE SWEDISH BY **D. O. BELL.**

STOCKHOLM:

PUBLISHED BY THE AUTHOR.

STOCKHOLM:
PRINTED BY CENTRAL-TRYCKERIET, 1898.

PREFACE.

This little work is intended to impart to my colleagues, and through them to the Public, the method which I have used for seven years in making plateless dentures.

Some may think it strange that I have waited so long before publishing a method which I considered good from the beginning, but I did not wish to rely entirely upon my own judgment; I preferred to let time and experience verify my theories. With the present tendency of scientific research, it is considered out of place to keep a good result to oneself; it has become customary to shrug the shoulders at "secret" knowledge, and the false conclusion is too easily drawn that there is no such thing. But is not this a mistake? Is it not wiser to wait and give one's contribution to normal development after having reached perfect certainty by strenuous labour?

Several details in my method have been improved during this time of waiting. Such as the method now is, presented, as I hope, with sufficient amplitude and clearness, I subject it to the kind judgment of my colleagues.

The illustrations in the book are taken from photographs of work done or of plaster models taken before or after the insertion of the prostheses. Thus some figures have not been rendered as distinct as if they had been drawn. This method of reproduction has, however, the advantage of insuring the reader that the work described is possible to be done, which is far from the case with many operations according to other methods treated of in literature, and which can be described and drawn but are practically impossible.

Finally, I beg to make use of this opportunity of presenting my gratitude to Dr. Algot Ruhe, who has assisted me at my clinic for a year and a half, thereby making it much more easy for me to present this work to the Public.

Stockholm, in April, 1898.

C. A. Samsioe.

TABLE OF CONTENTS.

PAGE

INTRODUCTION 9

CHAPTER I.

Dentures with Plate and Plateless Dentures 13

CHAPTER II.

Old Pivot Dentures 20

A. *Crowns manufactured on a large scale and joined to the pivot.*

1. The Logan Crown 23
2. The Brown Crown 24
3. The Richmond Crown 24

B. *Crowns joined to the pivot immediately before insertion.*

1. The Genese Crown 25
2. The Plug Tooth 25

C. *Crowns with Pivots secured in the root beforehand.*

1. Bonwill's method 27
2. How's Method 27
3. Foster's and Gates Methods 28
4. Perry's Method 29
5. Stowell's Method 30
6. Howland's Crown 33

D. *Crowns with Collar.*

1. Baldwin's and Townsend's Methods 36
2. How's Method 37
3. Kirk's Method 37
4. Pivot-tooth with Collar 38
5. Meriam's Method 38

PAGE

E. *Crowns with Collar, with or without pivot.*

1. The Richmond Crown 41
2. The Büttner Crown 42
3. The Richardson Crown 42
4. Parr's Method 43

F. *Fronts without Collar.*

1. Sach's Method 44
2. Law's Method 45
3. Leech's Method 46

CHAPTER III.

PLATELESS DENTURES.

Treatment of Teeth and Roots previous to the insertion of Plateless Dentures 49

1. Treatment of Living Pulps 52
2. Treatment of Gangrenous Pulps 59
3. Treatment of Pericementitis and Abscesses 64
4. Treatment of Gingival Fistula 67
5. Comparison with Witzel's Method of Preliminary Treatment 68

CHAPTER IV.

The Single Pivot-tooth. 73

1. The Fitting of the Pivot 76
2. The Fitting of the Porcelain Facing 79
3. How to make the Porcelain Facing and the Pivot. Impression 81
4. How to cast the Backing from the Impression 83
5. Insertion of the Pivot-tooth 85

Binding Element 87

Crown secured to the root of an adjacent tooth..... 92

CHAPTER V.

Detailed Specification of a large, special piece of work 97

CHAPTER VI.

How to make two connected Crowns 105

1. Two teeth with one pivot in one root 105
2. Two teeth with two pivots, each in its root 107
3. Two teeth with a pivot in one root and a collar around an adjacent tooth..... 110
4. Two teeth with a pivot in the adjacent tooth on either side 112
5. Two teeth secured by a pivot in one of the adjacent teeth and by a retaining extension to the other 113

Two teeth with one pivot in a root and another in an adjacent tooth 113

PAGE

7. Two teeth secured by a collar around an adjacent tooth and by a retaining extension to another 114
8. Two teeth secured by a collar around one adjacent tooth and by a pivot in the other 115

CHAPTER VII.

How to make three connected Crowns 117
1. Three teeth with two pivots, either beside each other or in the two outer teeth..... 117
2. Three teeth with a pivot in one root and a retaining extension 119
3. Three teeth with a pivot in a root and a collar around an adjacent tooth..... 119
4. Three teeth with a collar around one adjacent tooth and a pivot in the other 121
5. Three teeth with a pivot in the root of each adjacent tooth.. 121
6. Three teeth with one pivot in one root and another in the adjacent tooth 122
7. Cap with socket 123

CHAPTER VIII.

Specification of how to insert a larger number of teeth 125

CHAPTER IX.

A. Comparison with Witzel's Method 141
B. Comparison with Herbst's Method 144

CHAPTER X.

Repairs 149
1. Lesions of the Binding Element 150
2. Lesions of the Root 150
3. Lesions of the Pivot 152
4. Lesions of the Porcelain Facing 153
5. Repairs on a Denture without removing it 155

INTRODUCTION.

The conservative dental treatment which the science of the last few decenniums has given an admirable completion and an extensive popularity has, as yet, only relatively succeeded in revealing its influence on the prosthetic side of odontology. As yet hardly a single patient whose teeth have been rationally preserved from childhood has reached old age, and we therefore do not know the limits of our ability to defer the destruction of the crown of the tooth and the extraction of the root. But what we are already able to notice as a consequence of good fillings and a skillful treatment of roots is that the time for extractions is deferred longer than formerly and that the number of extractions is lessened. This state of things will, in course of time, bring about a complete revolution in the principles for the substitution of defects in teeth. Between the stage of tooth-treatment characterized by the filling of the crown, with or without treatment of the pulp, and the insertion of a plate, with or without the extraction of crownless roots, there will be introduced a new stage in which the roots and ad-

jacent tooth-crowns will be used as supports for teeth without plate.

By "teeth without plate" I mean artificial teeth secured in place not by a plate covering the roof of the mouth, but in such a manner that the size of the prosthesis will nearly correspond to the size of the defect. Thus under this heading come pivot-teeth and crown- and bridge-work, whether stationary or removable.

We know far too well that all, even the very best, dental work is subject to corruption. Between us and the powers that have a destructive effect on teeth there is a constant struggle, in which we can never hope to gain any complete victory. The most that we can expect in this respect is to postpone the final triumph of the enemy by treatment of the greatest possible durability. As long as we know almost nothing of means for strengthening the dental substance and do not know any other prophylaxis for caries than a sadly deficient hygiene, as long as the filling itself is principally only a palliative, as long as the therapeutics of orificial diseases has not yet reached its height and the teeth cannot be protected against the effect of constitutional diseases and senile degeneration, just so long will prosthetic odontology hold a more prominent place than the art of filling teeth. The efforts which have as their object to substitute an artificial crown without plate for the natural crown when it has wasted away are, considering the present standing of the filling-art, of just as great importance as the efforts to pre-

serve the crown. It is too simple a truth to be pointed out, that a patient has more use and less unpleasantness of his own teeth, even if they must be repeatedly filled, than of a denture on a plate. It should, at least in theory, be just as unconditionally recognised that a crown secured without a plate is likewise more useful and less unpleasant than a plate. But although every dentist fills teeth, in order to spare the patient as long as possible from wearing a plate, there are relatively few dentists who, by the skillful insertion of pivot-teeth, try still further to defer the extraction of the root. The reason why this kind of work has not succeeded in gaining the popularity which it deserves doubtless lies as much in the technical difficulties often connected with it as in the relatively high price it consequently incurs. The difficulty of the work and the long time which it frequently requires in order to do it properly, deter many a busy dentist, and the fee which necessarily must be charged deters the patients.

It is my intention in writing this work on plateless dentures to present a method which places moderate demands upon the strength and time of the operator, and which, at the same time, can be duly appreciated by the patient. The experience of several years has, besides, proved that this method fills the demands which can be made on work of this kind at the present stage of development.

CHAPTER I.

Dentures with Plate and Plateless Dentures.

With the guidance of the table given by Dr. George Evans* showing the points in favour of and against bridgework, I will here give the advantages which are generally attributed to it.

1. Perfect substitution of artificial teeth for lost natural ones, without the use of a plate.

2. Absence of the mechanical obstacles for taste or speech which attend the use of the plate.

3. The natural teeth are not worn by hooks and are not exposed to caries at the places which would be touched by a plate, so that the hygienic condition of the mouth is on the whole improved.

4. The denture is more solid and is always held securely in place even while speaking and chewing.

5. The weight of the artificial crown and the pressure of mastication are supported by the natural teeth or their roots which are better suited to withstand this weight and pressure than the alveolar process.

* George Evans: "A Practical Treatise on Artificial Crown and Bridge Work." Philadelphia, 1889.

6. Since all operations intended to substitute lost teeth must be considered rather as temporary than permanent as regards the final result, bridge-work takes, with respect to its durability, the same rank as, if not a higher rank than, other similar kinds of work.

In five paragraphs of objections against bridge-work, Evans states that, according to the opinion of opponents, such work cannot be supplied with artificial gums, that the self-cleaning intermediate spaces which, according to certain methods, occur in such dentures are filled with particles of food and impair the speech, and that the teeth used as supports are generally spoiled beyond repair by fitting crowns on to them.

As the most suitable corrective to these deficiencies may be suggested the use of artificial gums of enamel, f. i., where necessary, discarding self-cleaning intermediate spaces, chiefly because they have proved not to deserve this name, not putting crowns on healthy teeth, except when necessary, and securing the crown so as not to injure the tooth.

Furthermore, it is remarked that, when it is necessary to take out the bridge temporarily for repairs on account of disease in the supporting tooth, this is by no means easy and renders it very difficult or impossible to replace the bridge again. My rejoinder is: Try, as far as possible, to make the dentures removable.

The teeth that support a crown are exposed

to a greater pressure than was originally intended by nature, and if the bridge is permanently secured, neither the supporting teeth nor the tissues with which the bridge come into contact have time to recover from this train. "The final result is plain for everyone who has any experience in dentistry; and unless the anatomical conditions are exceedingly favourable, the utility and durability of such work will be decidedly limited, taking into consideration the time and high price which it necessitates."

The best way to avoid this latter disadvantage is obviously to try and apply a method of bridge-work, which besides filling the "anatomical requirements," does not take longer, is not more difficult or expensive than is compatible with the utility and durability of the work. As to the unnaturally strong pressure to which the supporting roots are exposed, it is, in the first place, not permanent, and, furthermore, far from acting injuriously, by putting to use hitherto unused roots, it makes them strong and fast. No irritation of the gums caused by the resting of bridge-work on them has ever been met with in dental practice, so that the above-mentioned time of rest for the implicated tissues is doubtless superfluous. It might be added, however, that a root cannot be loaded down with an unlimited number of teeth. Between two supporting points there should not be placed more than four teeth, according to a law stated later on, namely, that no tooth in bridge-work should be placed at more than one tooth's distance from a supporting

point, or, in other words, that no tooth without a fastening may have more than one tooth between it and a supporting-point.

The consequence of this will be that two cuspids, even under favourable anatomical conditions, may not support a whole row of teeth, but at the most ten. The fantastical drawings one sometimes sees of large dentures which stretch from one second molar to the other, or which are borne by a cuspid on one side and a premolar on the other side, can hardly be defended.

The inestimable services which dentures on plates, as long as they were almost despotic, have done for mankind, can hardly be too highly appreciated. Whatever objections may be made to plate-work, even in our days, when other principles for the treatment of teeth and for the substitution of defective teeth ought to be upheld, it should not be forgotten that this method is frequently unavoidable, and that it should always have a claim on a certain consideration, because it has once been the best method. Notwithstanding the advancement which has been made in plateless dentures in our time, we may not regard the development of plate-work as thereby completed or rendered superfluous. In the more and more limited number of cases when plateless dentures can not be used, all rational attempts must be made to reduce the defects and imperfections of plate-denture as much as possible by its perfection.

I dare say that, from a purely pedagogical

point of view, that work on plateless dentures makes one look sharper for the possibilities of variation in a plate, and causes the practitioner to place higher demands thereon.

Partial plates frequently bring about caries in places which otherwise are very seldom exposed to attacks of this kind, for instance the neck of the tooth on the palatinal surface. How seldom it is that a partial plate, after a few years of use, causes caries on the adjoining dental surfaces! The cause of caries in such cases is, of course, the difficulty in keeping the prosthesis clean. The condition of a mouth which is not given the most thorough hygienic care, will, after putting in a plate, be decidedly worse, on account of the great number of new points which the plate exposes to the attacks of caries. But even when the patient has the best intentions as to the care of the mouth, he is frequently hindered from following out his resolutions by lack of time and other circumstances. It is often quite impossible, for instance, for a person who takes his meals away from home to be alone for a sufficient length of time to cleanse a set of false teeth properly.

It may be frequently observed that patients with very defective teeth often neglect the requirements of the most primitive hygiene, and that, after necessary repairs and the insertion of a plate, they do not show any inclination to improve,— perhaps on account of the inconvenience connected with the frequent removal and cleaning. On the

other hand, patients who have been supplied with teeth without plate frequently make a radical improvement in this respect. One of the reasons for this is, perhaps, that it is more difficult for a dentist to convince an obstinate patient of the importance of keeping the plate clean without, to a certain degree, decreasing the patient's good opinion of the plate, while it is easy enough to convince a patient of the fact that plateless teeth should be treated with the same care as natural ones, in order to preserve them properly.

In using crown and brigde-work, the frequency of caries is certainly not increased, nay, we even go so far as to say that a suitable arrangement of such work can even remove many a threatening danger of caries.

It has been frequently remarked by opponents to large bridge-work, that such dentures bring on a cronical irritation of that part of the gums which they touch. In reply to this objection I can say that, in removing a bridge-denture of the tight-fitting kind made according to my method, it has been found that, although the denture had been worn uninterruptedly for several years, only a slight, immediately disappearing redness of the mucus membrane could be observed. This is the only divergence from an absolutely normal condition of the mucus membrane which could be observed on removing a large bridge-work which was in every respect correctly made and fitted and which had been worn for many years. This divergence from the normal condition, which

cannot even be justly called a disadvantage is so slight and disappears so suddenly that it can, without any danger whatever, be entirely overlooked.

If, on the other hand, we take into consideration the visible change which the gingiva and the palatinal mucus membrane with its subcutaneous tissues undergo when affected by a plate, it will be found that in many cases they show veritable signs of inflammation. The *rugæ palati* appear thick, indistinctly marked, red and soft, and we talk of "spungy gums." The impression of the suction chamber is plainly marked, the interstitial papillæ of the gingiva are hyperthrophied, the labial margin of the gingiva lies like a ridge up over the edges of the roots, and along the necks of the remaining teeth there runs a deep trench, as it were, palatinally bordered by a gingival wall.

I have in numerous cases, when a mouth in this condition was relieved of the plate, observed how easily the gums, where they come into contact with a well-fitting plateless denture, thus between the roots and, especially, at their labial margins, regain their normal colour and firmness.

CHAPTER II.

Old Pivot-dentures.

The great number of methods which have of late been proposed for substituting defective crowns on roots still intact shows, on the one hand, that the need of such a method is great and, on the other hand, that the proposed methods have not proved to be in all respects satisfactory. It is not my intention to give a description of the technical procedure in making different kinds of teeth, but rather, while indicating their characteristics, to show their weak points, which have led later inventors to present proposals for improvements or entirely new principals, — novelties which, in most cases, have shared the fate of their predecessors. On the whole, one may say in regard to the methods of making plateless dentures hitherto proposed that, notwithstanding certain merits, they have some weak point which prevents them from being commonly used. Some, in order to be correctly executed, require very difficult technical manipulations. The probability of an infallibly correct execution of the operation will obviously be less, in case the result is to be built up by a synthesis of differently com-

bined operations which must finally be brought into harmony with each other. This probability will be greater, however, if a method is used according to which the whole work evenly advances in development, so that every new stage implies that the immediately preceding stage was correctly gone through. Many of the methods which will be described below also require more indispensable conditions in order to make their use possible than are compatible with the great number of cases in which such work can be beneficial. The contra-indications coming from the very nature of the method become so numerous and unsurmountable that it never can be what such a method must be in order to be regarded as answering the purpose, namely to be popular in a good sense of the word. I do not wish hereby to say anything but good in regard to the results which really can be reached by the methods to which I have here referred when the necessary predispositions in the case and in the operator are present. There is, however, a different opinion in regard to some methods which, to be sure, cannot have a discouraging effect on account of their difficulty, but, on the contrary, by their easiness of execution, offer a temptation to careless use. In case such a method does not most accurately fill the majority of requirements which in other respects should be made on an ideal crown, it is decidedly repudiable. A method which is easy and nothing but easy does an enormous amount of injury by covering with discredit a method of tooth-substitution

as yet not commonly accepted. There are, finally, a couple of methods which, by their choice complication and doubtful worth are predestined never to be anything more than they have been, — an experiment and a fancy on paper.

That which all the pivot-dentures I intend to mention in this critical treatise have in common is that they all consist of a pivot to be fixed in the root-canal and a crown or part of a crown the front of which, at least, is to be made of porcelain. Within this extensive field a limit is then drawn between what I should like to call *crowns:* artificial enamel crowns which cover not only the front but also entirely or essentially the other surfaces of the crown; and *fronts:* artificial enamel crowns only covering the front, while the other parts of the crown are made of some other substance.

If we look at the entire crowns, we find in them an essential difference between such as are manufactured on a large scale and beforehand connected with the pivot, or which, by a special manipulation before insertion, are connected with it, and such as are secured to a pivot fixed beforehand in the root.

Under the former head come the Logan, Brown, New Richmond, and Genese Crowns, as well as the old pivot-tooth.

The Logan Crown.

The use of the Logan Crown has been and is still very extensive. There is a certain solidity in this crown which makes it pleasant to use, and it is very convenient to put into place. It is less adapted to whole series of defects, on account of the difficulty in overcoming a certain stiffness caused by the pivot and the crown being in one piece. The same thing makes it less applicable to crooked roots. For large roots not effected by caries and having a normal position, for instance the central incisors and cuspids of the upper jaw, it is very suitable, but, on the other hand, it is less suitable for slim roots, such as the incisors of the lower jaw. Otherwise, it has the same fault as all entire crowns, namely, that it is not as agreeable to chew on as a tooth with metal at the back, and, the same as most crowns of this group, has the weakness that the platinum of which the pivot is made must be very soft in order to be easily bent in fitting.

A serious disadvantage in this kind of pivot-tooth is that it must be entirely removed and replaced by a new one, in case it should suffer any essential lesion. When we consider how difficult it usually is to find a crown of this kind with suitable form and colour, this objection becomes very serious. It cannot be expected that a method which

for its execution requires a set of specially made teeth only suitable for use in a limited number of cases, can ever be universally applicable.

The Brown Crown.

I have an idea that the Brown Crown, with its convex base, was invented to fit on roots which are decayed beyond a certain limit better than a Logan Crown can fit in such cases. It would be difficult to discover any other merit in this crown, whose use also seems to be very limited, judging from the information which I have been able to collect by making inquiries at dental depots in Stockholm and several other cities.

The Richmond Crown.

The new Richmond Crown with its V-shaped excision seen from the side can, in suitable cases, be secured more tightly than its prototype the Logan Crown. Its utility is still more restricted than that of its pattern, since it cannot very well be applied to decayed or flat roots, a piece of healthy dentine being required large enough to be fitted into the V-shaped excision in the crown in order to secure it.

The Genese Crown.

The Genese Crown is an entire crown which, by a simple technical manipulation, is secured to its pivot before insertion. As is well known, the crown is supplied with a platinum-covered depression at the base, and, after being fitted, it is attached to a specially made pivot by being soldered to it in an open collar. This crown ought to be easier to fit than those that have the pivot secured to the crown beforehand. Strange to say, it does not seem to be very much used, although neither the difficulty in doing the little soldering on the platinum nor the slightly higher price could have deterred people from using it.

The Plug Tooth.

To this group of crowns should be reckoned the old pivot-tooth. In the depression at its base a wooden plug was carefully secured, either by mechanical means or by the use of a cement, and the whole was then inserted in its place. A certain calculation was made upon the propensity of the saliva to swell the wooden plug, so as to hold the tooth fast; but even on account of this very circumstance, which is, of course, very little in accordance with antiseptic principles, this

crown can only be said to have an exclusively historical importance. As being a new step, it aroused great interest, for it initiated the great revolution in the prosthetic part of odontology, on which we are still working.

Crowns with pivots secured in the root beforehand.

For securing an entire crown by means of a pivot which has beforehand been fastened in the root, methods have been suggested by Bonwill, How, Gates, Perry, Stowell, and Howland.

Bonwill's Method.

One of the oldest of these methods is that of Bonwill. The crown invented by Bonwill, a perforated porcelain crown, has, in more or less modified forms been retained by Foster and Gates and partially by How. On the contrary, his pivot has not been used by any of these inventors.

How's Method.

The method suggested by How for inserting a screw-post in the root has been accepted in all subsequent methods founded on this principle. In regard to this method, Dr. How says, among other things, the following*: "The difficulties and uncertainties in mounting artificial tooth-crowns on roots, by either

* Evans: Artificial Crown- and Bridge-work. Philadelphia, 1893, p. 49.

old or new methods, led me to a careful study of the problem, and resulted in a nearly simultaneous devising of several new forms of crowns and appliances for setting them, as well as a perfected method of performing the operation of fixing a peculiar screw-post in a root, and also a novel process of attaching the crown to the post." According to the description given of How's method, it seems to be so complicated that one is led to doubt the superiority of the final result. How has, however, made an important contribution to the art of making teeth without plate by presenting his method of making four-pin porcelain crowns. They may be used with great advantage in the method described in the latter part of this work. On the other hand, the screwing of a root is certainly an operation whose happy issue does not always depend upon the skill of the operator. It is true that a screw-threaded post can be set with perfect firmness, but the same result can be reached in another way.

Foster's and Gate's Methods.

The difference between Foster's and Gate's methods is in no respect essential. Both consist of a combination of How's post and Bonwill's crown in a somewhat modified form. While the Gate crown can sooner be identified with Bonwill's, Foster's more reminds us of a crown introduced by

Dr. H. Lawrence of Philadelphia in 1849, its basal cavity being smaller than that of the Bonwill crown. The post of these crowns is either supplied with a head or a little nut is screwed on to it.

Perry's Method.

According to Perry's method, a pivot-crown or a Howland crown is used,—an entire crown concaved sufficiently to receive one or several posts. This crown, like the Richmond Crown, is fitted on to the root which has previously been filed off V-shaped. An iridio-platinum post is secured with cement in the root-canal, and the crown is fitted on to it. Around the post the end of the root is concaved near the margin, and this concavity is filled with gold. The object of this is said to be partly to protect the root from caries and partly to give support to the post. Against this may be objected that a sufficiently strong post does not need such a support and that an eventual caries cannot be prevented by a gold-filling which leaves the outer margin of the root bare. The knowledge of this fact has led to the use of a variation, namely, in applying, instead of a gold-filling, a cap consisting of a collar with a cover of platinum, which is first connected with the post and then inserted.

Stowell's Method.

Stowell's method much reminds us of Perry's, wherefore the same objections can be made against this method as were made against Perry's. According to Stowell's method, the same kind of crowns are used as for the old pivot-teeth for substituting incisors and cuspids, while the Howland Crown is recommended for premolar and molar teeth. The pivot used by Stowell is How's screw-threaded iridioplatinum post.

That which especially characterises Stowell's method is a groove made on the somewhat concaved end of the root around the pin. This groove and the concavity are filled with copper-amalgam, the surplus of which is pressed away by trying on the crown, whose concavity, in its turn, is filled with cement and definitely put in place on the post.*

It is said that the copper-amalgam will protect the end of the root from all kinds of destructive influences and, like a ferrule, strengthen the support of the post. To this may justly be made the objection that in case a root on which has been placed an exactly fitting crown is really effected, it would first be effected in the periphery, wherefore it cannot be said to be preserved by a filling which does not reach all the way out to the

* Hans Riegner: Kronen und Brücken-arbeiten, Lpzg 1895, p. 40.

margin. But in reality the danger of caries is very small if the extremely minute suture between the crown and the root is filled with a hermetically sealing filling-substance which in itself cannot be effected.

In regard to the assertion that this copper-amalgam acts as a support or reinforcement to the post and as strengthening to the root, we must, to be sure, appreciate the endeavour to avoid putting a collar around the root, although there is room for a doubt as to whether the copper-amalgam can fill the functions of the platinum-collar. Furthermore, it is hardly doubtful that the weakening influence exercised by a concavity made near the periphery of the root cannot, in the long run, be counterbalanced by the solidity of a copper-amalgam filling. Taking the laws of leverage as a basis for our argument, we can prove that the shorter the part of the post that is inserted in the root, the less power is required to loosen it. Furthermore it can be shown that, if the distance between the fastening-points of the post in the crown and root is increased, the solidity is diminished in the same degree. These two points should, preferably, coincide. Therefore, there should not be any concavity in the base of the crown any more than in the root unless the post or the crown fills the concavity thus made in the root. My endeavours in this respect have tended to bring the post, root and crown in as intimate mechanical connection with each other as possible, and the results which I have

reached in so doing have been satisfactory, while endeavours in the opposite direction have not given as good a result.

It is without doubt that a cement or amalgam filling around the upper end of the post, by means of the continually repeated and very considerable pressure brought to bear during mastication, can be crushed and the post be bent or slip out, and the root itself, by means of the uneven distribution of the pressure thus incurred, can be injured. This danger is avoided, as I have said, by causing the cervical fastening-points of the post in the crown and root to approach each other so closely that they coincide.

A variation of Stowell's method, analogous to a similar one by Perry, consists in the use of a gold collar with cover, to which are soldered on the one side the post and on the other side a countersunk crown or a Logan Crown with the pins cut off. The peripheric margin of the end of the root is, as always in using a collar, made parallel with the longitudinal axis of the tooth, while its surface is slightly concaved. I am unable to see what advantage there can be in first cutting off the pins of a Logan Crown, and then soldering the two amputated ends to a cover with collar.

Howland's Crown.

This crown is secured by cement on one or several posts supplied with screw-threads and fastened by cement. It is also asserted that it is possible to secure the crown with guttapercha or amalgam. On account of the large concavity in the crown which is necessary in order to secure it in the aforesaid manner, the Howland method is used almost exclusively for premolars and molars. It is difficult to discover any special advantage connected with the use of this method, and the solidity of the crown is in many cases far less than might be desired.

Crowns with Collar.

A large number of the forms of entire crowns mentioned above may, in order to increase the solidity of the work, be combined with a metal cap pressed down over the cervical end of the root or by a metal collar covering the suture between the crown and the root. By the use of such a cap or collar it is true that the possibility of the dislocation of the crown is, to a certain extent, restricted, and the number of cases in which these crowns can be used on poorly preserved roots is thereby somewhat increased; but these advantages are reached by a means which tempts one to ask if the crowns which require such caps or collars may, on the whole, be considered suitable for use. Even in the writings of authors on this subject who see in the collar a necessary guarantee of the solidity of the work, we find statements which show that this means is not without considerable disadvantages. Thus Riegner* says: "It is, to be sure, an undisputed fact that collar-crowns, which are secured by means of a collar fitting tightly around the root and a pivot inserted in the root-canal, have proved to be the strongest and most durable of all crowns; but it may not be overlooked that, in many cases,

* Hans Riegner: Kronen und Brücken-arbeiten. Lpzg. 1895 p. 107.

in the proper preparation of the root for receiving the crown, a large amount of healthy dentine must be ground away which otherwise might very well have been saved to give the root greater power of resistance. In many cases it is necessary to desist from putting in a Richmond Crown, because by the retraction of the gums a slight trace of the gold collar becomes visible in course of time. Many patients regard this as a defect caused by the operator."

If we carefully consider these words, we cannot help being surprised at the Richmond Crown being put forward as a kind of scape-grace for the collar in general. There is no doubt but that the retraction of the gums, which makes the Richmond Crown less desirable by exposing the collar, will also take place when other kinds of collars are used, thus making their use an expedient rather than a model method.

The same author with due cause warns against the lesion of the gums in grinding the labial margin of the root. If this should take place, the injured gums will retract in healing, thus causing the collar to be visible on the labial side. There are grounds for supposing that a *restitutio ad integrum* is not so easily reached when there is a *corpus alienum* on the outside of the root and between this and the gum. In the rather considerable gingival excisions which must sometimes be made in order to make certain subgingival cavities accessible for filling, the cicatrizing in most cases takes place without

noticeable contraction, the filling not acting as a foreign body.

There is, besides, the senile contraction of the gingiva, against whose progress we stand almost powerless. Even if we only regard this quite hypothetically, its influence upon the denture with a collar will be in a high degree disastrous.

The best way to avoid difficulties is to base the work on the principle of the exact fitting of the crown to the labial margin of the cervical end of the root which is ground off below the gums, in which case there will be no retraction, and the results of a physiological or eventually pathological retraction will have no influence on the durability and appearance of the work.

In the special section of this work I shall more minutely describe the methods which can lead to such a result.

Baldwin's and Townsend's Methods.

In two cases the Logan Crown has been used in connection with a collar reinforcement. According to Baldwin's method, it is used with a cap fitted around the end of the root and soldered to the pin; according to Townsend's method, the cervical end of the root is embraced and the suture between the root and the crown is covered by a collar. While Baldwin's method requires a root of about the same solidity as is necessary when an ordinary Logan Crown is used, Townsend's method is to be

recommended for deep roots, especially such as are laterally decayed.

How's Method.

Even How's dovetail crowns may be secured by a collar, in whose centre is placed a cap covering the end of the root. On one side of this cap the pin is soldered and on the other side a tube of the same size as the opening of the excision in the crown. This tube is slit into four parts before the cap is cemented on to the root. Then the crown is secured, also with cement, on the slitted tube, and when the cement has hardened, the bottom of the tube is filled with tin-gold alloy, in order that its four divisions may be driven into the dovetailed excision in the porcelain crown. The filling is finished with gold.

One cannot help being astonished at the erudite speculations upon which this complicated method is founded. It can be carried out; of this there is no doubt, but it can justly be made a matter of inquiry, whether the result will correspond to the pains.

Kirk's Method.

Kirk suggests a combination of Foster's Crown, How's or some other screw-post with a head, and a gold collar. After these three parts have been fitted together, the collar and crown are fixed in place with cement, and into the root-canal filled

with cement the pin or post is screwed and should be carefully fitted into the screw-threads in the root. The method ought to give good results, but its use is considerably restricted, since it is only suited for molars and premolars.

Pivot-tooth with Collar.

In order to avoid the disadvantage in the pivot-tooth that its wooden peg may incur by swelling and bursting the root, and to prevent the bad effects caused by the crown not fitting tightly to the root, thus freely admitting mucus and particles of food, the pivot-tooth has been combined with a metallic protector consisting of a tube which is inserted in the canal, a cap or cover over the end of the root, and a collar covering the suture between the root and the artificial crown. The metal frame is secured with cement, while the crown and the wooden peg (relying on the expanding power of the saliva) are inserted in the tube and collar.

This method has not, however, by this change taken any important step towards filling simple antiseptic demands. Now as formerly the wooden peg must first be soaked with saliva and microbes before it can do its duty.

Meriam's Method.

A uniquely original method for putting on crowns has been invented by Dr. Meriam. Around

the suture between the root and the crown, which is in this case countersunk, there is passed a gold collar which is secured in place around the root by means of cement. A gold wire is twisted in a special manner, so that part of it can be tied around the little platinum knob of the crown and another part be inserted in the root, thus serving as a pin. It is said to possess great durability, but strikes me, at all events, more as an attempt to invent something new than as a fertile principle which deserves being followed.

Crowns with collar, with or without pivot.

It does not seem to be necessary to present here the details in the execution of this kind of work, which is treated at length in handbooks and other special works. Neither do we need to repeat here the criticism to which in the preceding chapter we subjected some of the elements which form a part of these methods of pivot-denture, f. i. the collar.

The advantages which can be reached by the use of these methods are commonly recognised; their adaptability to roots of more varying form, length, and position than is the case with the methods we have before described, and the circumstance that they admit of the use of current flat-tooth types, have justly won for them a prominent place in the competition between the numerous principles which have been tried during the course of years. The method which, in its turn, will be able to take the place of these methods founded on the use of a flat tooth with collar, must, obviously, not only possess all the advantages owned by these methods, but must also prove to be free from the weaknesses with which they, on the other hand, are undeniably encumbered. Among these disadvantages, the grinding of the cervical margin

of the root which is necessary for the application of the collar doubtless takes the first place. If we furthermore mention that the junction of the base of the crown with the end of the root cannot always be so nicely carried out in the finest details, that the technical work often consumes an enormous amount of time, and that this, in connection with the expensive material, in certain cases prevents these methods from being used, since some attention must be paid to the price of the work, I think we have added the principal objections which can furthermore be made to this kind of denture.

The Richmond Crown.

The classical type of fronts with collar and pivot is the Richmond Crown, which should not be confused with the *New* Richmond Crown, which has already been mentioned.

The fundamental elements of the Richmond Crown consist in the pivot, the collar with cap, an ordinary flat-tooth with a backing, and a solid gold palatinal wall. Disregarding the general weaknesses which have already been sufficiently dwelt upon, this crown is solid, elegant, and very easy to apply.

The Büttner Crown.

Büttner has very happily endeavoured to reduce the labial, visible margin of the collar still more than is possible in other methods, without thereby decreasing its strength. By the aid of instruments especially made for this purpose, the end of the root is made cylindrical and is provided with a platinum cap whose size corresponds to the root-trimmer used in every special case. The porcelain tooth is not only ground to fit the root, but is also provided with a suitable depression, so that it will, as completely as possible, cover the labial portion of the root-cap. Pivot, cap, and porcelain crown are soldered together and are supplied with chewing-cusps, after which the work is polished and inserted.

The Richardson Crown.

In this connection we ought, mostly for curiosity's sake, to mention the Richardson Crown, consisting of a flat-tooth with collar and palatinal contour of vulcanized rubber. I have not been able to find any information in dental literature as to the advantages of this crown, and I must confess that it is impossible for me to find them myself.

Parr's Method.

Dr. Parr uses two caps, one which is fastened around the end of the root and another which is connected with a post and crown and accurately fits on the root-cap. By means of this arrangement the crown can be removed without thereby disturbing the root. For this reason the method is recommended especially for removable dentures of large or small dimensions.

Fronts with Collar.

A considerable advancement in the perfection of the form of pivot-teeth has been made by the use of fronts without collar. But the idea of securing a front without using a collar seems, as it were, to have frightened the inventors of crowns of this pattern, so they have sought a substitute for the collar in several more or less complicated and superfluous arrangements.

Sachs's Method.

According to a method invented by Dr. Sachs of Breslau, there is inserted in the properly prepared root a star-shaped tube which is closed at its upper end, and along the exterior of one of its sides provided with a toothed edge 2 or 3 mm. long, for which place has been prepared in the strongest part of the root. Besides longitudinal grooves and the toothed metal edge soldered to the tube, it is, by means of a wheel-shaped drill, supplied with suitably disposed transverse grooves, all for the purpose of fixing the tube securely in the root-canal, and in order to do this all the more thoroughly, the end of the root is concaved around the tube, is supplied with undercuts and is filled with gold or amalgam, a coffer-dam being used in

the operation. This is what we might call quadruple certainty! The pivot used is, like the tube, longitudinally grooved and should fit perfectly into the tube. A flat-tooth with backing is soldered to the pin, after which the work, without any binding substance, is simply inserted into the tube. It must be here pointed out that we have to do with a crown in which no positive respect is paid to articulation.

Neither from the letterpress nor from the illustrations of the descriptions which have come to our notice can it be seen that any care has been taken with the palatinal contour of the crown for the purpose of bringing about correct articulation.

As long as it is possible to bite the teeth together, it seems that nothing else is demanded of articulation.

Low's Method.

According to Low's method, specially made "step-plugs" of platinum or nickel, acting both as pivot and protecting-cap for the root, are used. There are seven sizes of cutting-instruments, and corresponding exactly with them seven sizes of the step-plugs. The front-crown is ground to fit the root and is tried in connection with the plug. In soldering, there is formed, if possible, a palatinal contour, and the work is set with cement.

Like many other pivot-tooth methods, this also possesses certain advantages, but requires, in order

to be used, a combination of favourable circumstances, which fact will doubtless keep it from ever coming into general use.

Leech's Method.

Leech suggests the use of a tubular pivot exactly fitted to the root-canal, which should be somewhat wider at the bottom than at the top or entrance. To this tubular pivot is connected beforehand a little plate fitting the end of the root and to this a front with backing. The tube is slit down two-thirds of its length into two or more parts. On inserting, a thin layer of gutta-percha is laid over the base of the crown to fill the space between it and the end of the root. Through the palatinal opening of the tube tin, tin-gold, or gold is introduced, the metal being packed to such a degree that the slit walls of the tube are forced apart and pressed tightly against the walls of the root-canal. If this filling is removed, it will be easy to remove the crown if necessary. This is without doubt the only case in which an inverted conical enlargement of the root-canal is suggested for securing a crown. Although this operation near the apex of the root cannot be considered otherwise than dangerous for the solidity of the root, we are obliged to give recognition to the originality of the idea.

PLATELESS DENTURES.

CHAPTER III.

Treatment of Teeth and Roots previous to the insertion of Plateless Dentures.

Before I go on to the detailed description of the preliminary treatment which must be given roots and teeth previous to the insertion of a plateless denture, I should like to make a few remarks in regard to the general demands which can be made both upon the final result of these operations and upon the manner of their execution.

In the tooth-filling science, the question of the preservation or cauterization and amputation, or extirpation of the pulp is still a matter of debate. It is still an open question whether the part of a root-pulp left after the amputation of the crown-pulp can be regarded as capable of causing any later unpleasantness after antiseptic treatment and filling. On the contrary, it seems to be confirmed that a tooth whose pulp after proper cauterization has been entirely extirpated and substituted by an antiseptic or aseptic filling can be said to be perfectly protected from further infection.

We take it for granted that the same gracious prognosis is, by most operators, applied to a root-

filling in a tooth whose devitalized, suppurating or gangrenous pulp has been entirely and correctly cleaned away from the root-canal or whose pericementum has showed symtoms of an incipient or even a more advanced acute pericementitis, if only it has once been perfectly cured. If we now consider that. on account of the very nature of the pivot-tooth, only such methods can be used in pivot-tooth work as can afford the very best prognosis, the demand for an accurate treatment of all the affections of the pulp and all the acute affections of the pericementum must be regarded as indispensable.

To this favourable prognosis for cases which hitherto have, to a certain extent, been supposed to be, if not entirely incurable, at least severe and frequently uncertain, both the choice of the filling-materials and the manner of applying them have contributed in an essential degree.

Even if the methods and means which we have here generally characterized certainly lead to a good final result, we have not thereby filled all the demands which may be made on a rational preliminary treatment of roots. This ought really to be done without pain to the patient in order to be regarded as good.

The cutting off of a crown and the immediate extirpation of a pulp are operations which can, to be sure, be successful, but which, on account of the pain connected with them, must be considered as less suitable. It must be remembered that the

patient in his opinion of a piece of work is frequently far less competent to judge of its final worth than of the unpleasantness connected with its execution. The humane side of the dental profession, the dentist's struggle against pain and his care not to cause suffering may not stand in the way of his operative endeavours.

In order that the form of substituting teeth which will be especially described in this work may be able to take the place in general knowledge to which it is, in the course of development, entitled, it must, not only in its final result, but also in its execution prove itself to be less unpleasant and more reliable than other prosthetic systems.

Treatment of Living Pulps.

In case a living pulp exists in a tooth whose root is not to be used as supporter of a pivot. it must be made senseless by the application of arsenic previous to its extraction from the canal.

If the arsenic is applied with sufficient care, it will only in exceptional cases cause pain for a short time. In most cases, and especially if the pulp is previously healthy, no matter whether it is covered with dentine or not, the killing of the pulp is accomplished without unpleasantness for the patient. If we furthermore take into consideration that the crown of the tooth or remaining portions thereof can be removed with greater certainty and less pain by means of drilling than by cutting off, the quick-method used by many for this purpose must be regarded as less rational than time-saving.

The method to which I refer consists, as is well known, in cutting off the crown of the tooth and, during the shock thereby caused in the pulp, when the pulp is said to be senseless, in executing a heroic extirpation. Besides the danger of fracture or uneven cutting-surface which easily occurs when the tooth is cut off in this manner, there is great risk of causing the patient excruciating pain. The anaesthesis of the pulp which is brought about by the shock frequently is quite momentary, so that

every complication, or anything that delays the ex tirpation, makes it painful in the highest degree.

In treating a living pulp in a tooth which is to be used as a support for a pivot-tooth, the proceedure is somewhat different, depending upon whether the pulp is infected or healthy.

If the pulp is exposed or covered by dentine which is decayed down to the very pulp, and if it aches severely during the operation, the immediate application of arsenic should preferably be avoided. First after the pain has been deadened by the application of an anaesthetic, f. i. oil of cloves and cocain, *ana partes*, a slight quantity of arsenic-paste to which has just been admixed about the same amount of cocain-crystals can be inserted on a little wad of cotton and preferably applied to the exposed pulp. The arsenic should, in every case, be administered before the operation is over, even if it has not been possible to relieve the pain entirely. It is hardly necessary to point out that the arsenic should be applied without there being any pressure brought to bear on the pulp, and that great care should be taken in covering the arsenic that no unnecessary pressure is caused. In order to make it easier to cover the arsenic applied to the pulp, without pain to the patient, a little cap may be placed over the arsenic with its concave side turned towards the pulp.

The chief demand which is here made on the covering is that it hermetically encloses the arsenic. It should also be easy to put in and to take out

again. For rather deep cavities, guttapercha is therefore very suitable, while for shallow cavities, a thin, sticky cement, f. i. Harvard cement, is preferable.

In forty-eight hours the pulp is, as a rule, so senseless that at least the part contained in the crown can be removed and frequently one may even extirpate it entirely and immediately fill the root. If sensitive tissues are found in the root-canal, there is nothing to hinder a renewed application of arsenic, even rather high up towards the apex of the root. I cannot consider the current fear of administering arsenic in the root as anything but a prejudice. If during this treatment the patient's tooth is daily inspected and small quantities of arsenic paste are successively used, the canal being gradually enlarged as the anaesthesis advances, there is no danger of the pericementum becoming sensitive. If, however, there is any noticeable soreness when pressure is brought to bear on the root, one may rest assured that it will disappear after a time if the treatment of the root has been correctly carried out.

The periods of time given here are, generally speaking, only approximate. It may be advisable to let the arsenic remain in the tooth for a shorter or longer time, according to the diameter of the root-canal, depending upon the kind of tooth being treated, upon the age of the patient, or possibly existing new formations. In wide canals the cauterization will take place in a shorter time than in more narrow canals.

As soon as it is certain that the pulp is senseless, the remaining portions of the crown of the tooth are removed, after which one should proceed to the preparation of the root-canal.

The amputation of the remaining portions of the crown is done in such a way that the enamel is first cut through with a sharp gem or carborundum wheel both on the labial and the lingual side, after which the cutting of the dentine is continued with a fine fissure-drill until the crown can be broken off by a slight pressure. After having thus acquired access to the root-canal, the remaining portions of the pulp are removed by means of a flexible drill or a Donaldson spring-tempered canal-cleanser. In narrow roots where a nerve-extractor cannot well be used, a passage is made in the canal with fine drills.

After all the remaining portions of the pulp have been removed, the canal is widened by means of an Ottolengui root-trimmer to the size of the pivot. Now the apical filling is inserted. In case the operator prefers, he may insert the root-filling previous to the reaming out of the root-canal.

Partly guided by Miller* the following requirements may be presented as desirable or indispensable qualifications of the material to be used as filling for pivot-tooth roots.

1. The material itself ought not to be capable of undergoing putrid decomposition.

* W. D. Miller: Lehrbuch der conservirenden Zahnheilkunde. Lpzg 1896, pp. 342—343.

2. It should be capable of exercising a prolonged effect, even if it is but slight. In the cases when one is certain of having removed from the canal every trace of putrid substances, this property is not indispensable. In such cases, I frequently content myself with the antiseptic filling which is formed by the pivot and its binding-element.

3. It should be easy to insert and have such qualities that it can be carried all the way up to the foramen apicale.

4. It should not exercise any strong and, above all, no prolonged irritation on the periecementum or on the periapical tissues.

5. It should preferably not discolour the root.

A substance which, according to our judgment, best fills the above demands is carbon-wad (Dr. E. Förberg's), used as a vehicle for some antiseptic, f. i. eugenol.

A little carbon-wad is slightly soaked with eugenol, is inserted into the root-canal, and is forced up to the apex by means of not too fine a root-plugger. A slight condensing and a simultaneous wiping of the walls of the canal is accomplished by means of a finer root-packer wound with cotton. After thus having finished the root-canal treatment proper, we proceed to the preparation of the cervical end of the root, as described further on.

Before leaving pulp-treatment by arsenic, we ought, perhaps, to mention the modifications to which it must be subjected as soon as the pulp is not, as

in the case above described, exposed or covered only by dentine decayed all the way up to it.

If the decayed dentine has not yet reached the pulp, and the pulp is according to all symptoms, healthy, arsenic may be introduced into the cavity immediately, after a very slight excavation, notwithstanding the fact that the pulp-chamber is perfectly closed. If the pulp is healthy, it is made insensible together with the covering layer of dentine by one or two days' effect of the arsenic, without any preceding pain. The pressure which is exercised on the nerves of the pulp by the hyperaemia caused by the arsenic does not cause pain in these nerves if the pulp is healthy when the arsenic is applied. Only in case the pulp is infected and its nerve-elements inflamed, does the arsenic cause a short painful irritation. It might be said that there is the same difference here as there is between the effects of a light pressure on an inflamed part and on a healthy tissue. Even the slightest touch on an abscess is very painful, while a rather strong pressure of the hand does not hurt in the least.

Twenty-four hours after the first application of arsenic, the dentine is usually perfectly indifferent, so that the pulp may be exposed without pain to the patient. Arsenic is then again layed on the exposed pulp, after which the treatment of the root can, as a rule, be carried out the next day.

In certain cases, it may be necessary to cauterize the pulp in a tooth with an intact crown, f. i.

when the root with or without the crown is to be used as a support for a pivot-denture.

If it is the intention to preserve the larger portion of the crown, the enamel is cut through with a gem or carborundum wheel in a place where the pivot is to enter the crown, after which the operator penetrates into the dentine as far as the patient can bear. If it is, however, the intention to amputate the whole crown, the point of perforation of the enamel is either placed at the cutting-edge or on a cusp. In this place the dentine is generally less sensitive than at the tooth-neck, so that a deeper penetration is rendered possible. In the cavity thus made arsenic-paste is inserted, covered and held fast by a sticky cement. The day after this insertion, the sensitiveness in the dentine is generally so much decreased that it is possible to penetrate, without unpleasantness to the patient, so deep that the arsenic thereafter applied will more directly effect the pulp. As a rule this second application can be left undisturbed for two days without danger of unpleasant sensations either in the pulp or in the periosteum.

After the pulp has well been reached, the treatment is continued as above described.

Treatment of Gangrenous Pulps.

If the pulp is entirely decayed but the periosteum perfectly healthy, the success of the operation depends, in the first place, on preventing the infection in the root-canal from proceeding through the apex. In this case it is of great importance to the prognosis to know with perfect certainty that the root has neither been nor is at the moment affected by any periostic disease.

Unless the root reacts on percussion, and if the gingiva does not, by redness or traces of an old fistula-opening, betray anything which bids one be cautious, there is great cause to suppose that only the canal is infected. Since, as stated above, the possibility of an immediate filling of the root chiefly depends upon preventing the infection from spreading further, special care must be taken in cleansing the canal.

The methods generally suggested for removing the putrid substances which obstruct the root-canal seem to me to be more or less uncertain. By means of a fine extractor, or the like, wound with cotton, the contents of the canal is gradually removed, according to these methods. See, for instance, Miller's work: "Lehrbuch der conservirende Zahnheilkunde," p. 329. In other methods a galvanic cauterizing wire or loop and syringe-tubes or the like play an

important part. It cannot be denied that in filling, the difficulty of access to the canal is frequently so great that many a means must be resorted to in regard to whose certain effect one cannot be fully convinced. In the preparation of roots for pivot-teeth, however, the mechanical predispositions are generally so favourable and the access to the root-canal so easy that the cleansing of the root-canal ought to be done in an infallible manner.

The cleansing of the root-canal should be done in the following manner. Perfectly free access to the root-canal is procured by amputation of the remaining portions of the crown. After having dried the end of the root by slightly touching it with bibulous paper or spunk a flexible drill whose head is about the same diameter as the root-canal is introduced as far into the canal as it will go of its own accord with one or two revolutions, the pedal of the machine being moved very slowly in so doing.

The drill is now taken straight out and cleaned with the machine running backward. Then it is reinserted and taken out again and so on, each time going a little higher up and removing as much matter as will stick to the head of the drill. The higher up towards the apex we come, the more care must be taken that the drill is, as it were, screwed up into the canal, fed on by its own spiral. On approaching the smaller portions of the canal, the drill is exchanged for one of smaller size and so on. It should be remembered that this drill is not to be

used for the expanding of the canal and that it therefore does not need to be of the same or of a greater diameter than the canal. Care should be taken to prevent the drill from acting as a piston which will be the case if too large a drill is used or if it is pressed too fast up the canal. Since the contents of the root-canal is frequently half-fluid, pressure is transmitted by it the same as by a liquid, namely, equally in all directions. A careless pressure at the cervical opening of the canal is consequently capable of causing rather fatal results at the apex.

If it seems to be apparent that the end of the root is somewhat crooked, it is best not to continue, but depend upon neutralizing the remaining slight quantity of putrid substances in the antiseptic.

After the canal has been cleansed, the filling of the apex of the root can immediately be undertaken. The root is dried throughout its whole length with hot air or with some suitable mechanical appliance, and a little wad of carbonic cotton saturated with eugenol is passed up the canal, but without being pressed too strongly up towards the apex of the root. Outside of this is laid a little loose cotton tampon with some weak antiseptic, f. i. phenol-spirits, and at the mouth of the root an hermetically closing gutta-percha-pellet.

In cases where the form of the root-canal gives cause to doubt whether it has been possible

to cleanse the canal all the way up to the apex, and in roots which, by a more prolonged effect, seem to be very strongly saturated with putrid liquids, in case of gangrenous humours of long standing, it can be regarded as suitable, before putting in the final root-filling of carbonic cotton, to insert temporarily either a paste of iodoform with eugenol or formalin, which is allowed to remain twenty-four hours.

A fine root-plugger is dipped in a paste of deodorized iodoform of about the consistency of syrup and a rather strong formalin solution in such a manner that a portion of the paste sticks thereto. The root-plugger and the adhering paste should, together, be of about the same diameter as the root-canal. Just before the root-plugger has quite reached the apex, the paste is rubbed off against the walls of the canal by giving a rotating motion to the end of the plugger, which is then drawn out in such a way that an open passage is left in the root. Stress should be laid upon the fact that the mass is not pumped up, since it then can neither be estimated how great a quantity has been introduced nor where it has been placed.

After this treatment, the patient should be instructed to come back as soon as the least unpleasantness is experienced. If no unpleasant symptoms have appeared, the above-described permanent root-filling is introduced into the apex. If, on the other hand, a slight soreness has been felt, the

operator may either apply tincture of iodine to the gums and wait another twenty-four hours to see the effect, or immediately begin the treatment of the commencing periostitis, as described in the following.

Treatment of Pericementitis and Abscesses.

If the root to be treated is affected with acute pericementitis, it should be cleansed, with just as great care and in the same manner as in ordinary cases of gangrenous pulps, from decomposed pulp-remains, after which, with a very fine flexible drill the apex is carefully approached, with pauses between the different insertions of the drill, in order to let blood and pus escape.

If no such issue appears and the pericementitis has only existed for twenty-four hours, only expressing itself in soreness and swelling, an immediate perforation should be avoided, the case being treated, instead, as above described for certain cases of gangrene, i. e. with a temporary application of iodoform and formalin, painting the gums with the following solution:

Rec. Sol. iod. spirit. 10 grams.
Tinct. aconit. 5 "
Chloroform. 2 "

In case of swelling, the treatment may not be considered to be finished before the above mentioned flow of pus has appeared, i. e. before the abscess has been opened. In many cases it is not necessary for this purpose to penetrate all the way to the apex,

since it frequently happens that the pus, on account of the strong pressure, spontaneously issues on the opening of the entrance of the canal. Otherwise, it is necessary to go further, and it is then, with a little practice, very easy to feel when the head of the drill has passed through the apex, thus avoiding an unnecessarily deep penetration into the alveole. After the apical opening has been cleansed, the ensuing escape of blood and pus should be waited for, and the canal can then be mechanically cleansed from impurities and dried either with hot air or a galvanic cauterizer connected with a silver wire (Amoedo model).

In the well cleansed and dried canal, the iodoform-formalin paste is afterwards introduced as described above, but should not be pushed all the way up to the apex of the root. In consideration of the important part played by antiseptic gases in certain cases and the ease with which formalin volatilizes and penetrates solid bodies, it may be supposed that the formalin in this paste exercises a direct quieting and sterilizing effect on the periosteum. The iodoform principally plays the part of a suitable vehicle, but on account of the constancy in the effect of the formalin, the periosteum might become irritated if subjected thereto for any length of time. It is therefore advisable to remove the iodoform-formalin paste the next day, and, in case the pain has disappeared, replace it with a permanent, indifferent apical filling consisting of carbonic cotton saturated with eugenol.

If the patient is able to return as soon as the slightest increase of pressure in the tooth is felt, a new application of iodoform-formalin may be made; otherwise it is advisable to let the root-canal remain open till the flow of pus has entirely ceased.

This operation is very gratifying, — the pain ceases in most cases soon after the evacuation, and relapses are rare exceptions which may possibly somewhat delay but by no means frustrate the final result.

Treatment of Gingival Fistula.

In cleansing a root with an abscess which has already perforated the gingiva, it is not necessary to be as cautious as in the above described case. After having prepared a free passage through the enlarged root-canal, the canal, the abscess, and the fistula are forcibly syringed out with some antiseptic solution.

It is not necessary repeatedly to syringe out the fistula through the root-canal, wherefore it can very well be filled immediately with carbonic cotton and eugenol in the apex, and the fistula is either left alone or treated from without by probing it a few times with a root-plugger wound with cotton dipped in a mixture of one part of sulphuric acid and two parts of ether.

It deserves to be mentioned that in this probing an attempt should be made to penetrate deep down into the fistula, or as a rule, nearly 2 cm. Hereby the concentrated sulphuric acid cauterizes the torpid granulations and refreshes the walls of the fistula which thereafter are easily healed.

In case the fistula is very old and in spite of this treatment does not show a tendency to heal, an operation will doubtless be advisable in order to remove dead bone-tissue.

Comparison with Witzel's method of Preliminary Treatment.

In order to show with more clearness the characteristics specific to the above described method of the treatment of roots to be used in pivot-tooth work, I will here present a short comparison between this method and that used by Witzel.* Out of the many different methods for the execution of such operations which have been presented in course of time I choose Witzel's, partly on account of the great authority which his method possesses, or at least has once owned, partly on account of its completeness, and because, founded as it is on antiseptic principles, it cannot be said to be entirely antiquated. There is no doubt whatever that today, twelve years after the publication of Witzel's epoch-making work, many dentists follow in detail the doctrines he laid down,—and are satisfied with the results reached by him; and it cannot be denied that even in relation to a method of treatment which in our day is to make claims on being painless and sure, Witzel's method stands out as an estimable departure bearing fruit by its deep conception of certain fundamental ideas but (for the good of science) already, in many instances, exchanged for methods with much greater claims. The fact that Witzel's book on re-reading so few years after its publication has such a striking

* Compendium der Pathologie und Therapie der Pulpakrankheiten des Zahnes von Dr. Med. Adolph Witzel. Hagen i W. 1886.

"historical" effect gives a highly favourable testi mony for the work done since then in our profession, and does not by any means need to be regarded as disparaging either for the work or its famous author.

An obvious difference between the method described in this chapter for amputating a crown from a root to be used as supporter of a pivot-tooth and the method recommended by Witzel in § 291, gives a clear idea of the increased respect now paid to the nerves of the patient.

While the pulp was still alive, Witzel made a labial and a lingual incision in the crown of a central incisor with an emery-wheel (Carborundum was not yet discovered). In these groves the jaws of the tooth-clipper were applied and a part of the crown was cut off, "generally opening the pulp-chamber, but never to such a width that the extractor could immediately be introduced to remove the pulp. In order to extirpate the pulp, that portion of the pulp which lies exposed, must, as soon as possible, be pushed back from the place of perforation by means of a blunt root-plugger, and the entrance to the pulp-chamber must be enlarged around its whole periphery. Hereafter the pulp, previously anaesthetized with phenol, is extracted with antiseptic precautions, and the apex of the root-canal is filled. Sometimes the root-canal is so narrow that the pulp cannot be taken out with a nerve-extractor, but a spear-shaped drill must be used."

The following points in regard to this method are especially noteworthy: —

1. Grooves are ground in the crown while the pulp is still alive. 2. The crown is cut off. 3. The pulp is extirpated while alive. 4. If the pulp cannot be extirpated, it is drilled out while alive.

It makes one shudder to see how the one of these operations exceeds the other in cruelty. If the cited anaesthetizing with phenol were really effective, a whole revolution in our profession would thereby have been brought about. This is, however, not the case, as is well known. By way of comparison, I might mention that this operation, according to the method described by me in the preceding chapter, has the following stages: 1. The pulp is cauterized with arsenic, without pain, because it is healthy. 2. The pulp is extirpated after it has been made entirely senseless. 3. Incisions are made through the enamel quite near the labial side and so high up on the lingual side that no more grinding worth speaking of is necessary there. Then the crown is cut off by means of a fissure-drill. In this way a slow and disagreeable secondary grinding is avoided, besides which the root can never split.

Many an old and renowned practitioner will doubtless find this method unnecessarily circumstantial and careful, referring to the speed with which he cuts off the crown and extirpates the nerve in one operation without the patient com-

plaining so very much. I do not doubt in the least that it is possible to convince a patient of the necessity of an heroic method, and that it is even possible to get him to say that it did not hurt very much, but the memory of the shock will surely return with such force that when the patient is once more in his home and surrounded by his family, he will not repeat the same mild opinion as he expressed to the dentist. Everybody must see what obstacles are put in the way not only of this special operation but of the treatment of teeth in general by such a painful treatment. The humane properties of which I have spoken in another place only need to be mentioned in order to be appreciated to their full worth. In reality these, together with the surgical properties of the method should first be taken into consideration in operations which may give pain.

In § 294 Witzel describes the manner in which he treats a root in which there is a gangrenous pulp and whose alveole is also infected. Using nerve-extractors and 20 % sublimate of mercury, the root-canal is cleansed and is sealed with cement. After three or four days' observation it will be suitable to fill the root-apex and to a certain degree the abscess-hole with sublimate-cement paste and prepare the root-canal for receiving the pivot. If, in roots that have been open for a long time, there should be a slight pain in the alveole already the second day, a perforation of the apex of the root with a capillary root-plugger will be ne-

cessary (§ 296). The use of tube-pivots is dissuaded, "although repeated inflammation and swelling of the alveole after putting in a pivot-tooth is not impossible." And in § 298 he says furthermore: "The operator must beforehand call the attention of the patient to this swelling of the alveole, so that he will not feel anxious about it."

To this the objection may be made that sublimate should not be used unless in special, exceptional cases, since it discolours the root, as is well-known. This is a cause of great unpleasantness to people who show their gums, since the black root frequently shows through the gum and gives it a disagreeable, dark appearance.

Witzel's method is, besides, altogether too time-killing, without offering any sure guarantees of a happy result. It is nowadays considered to be a requisite of good order that the treatment of pericementitis and the preparation of the root-canal is finished before the denture is put in. In case of chronic pericementitis, or the like, it is clear that a somewhat reserved prognosis must be made, keeping it possible to resume the treatment through the apex, fastening the work with guttapercha.

CHAPTER IV.

The Single Pivot-tooth.

We have already presented as a peculiarity in this method of making plateless dentures that the same principles according to which a single pivot-tooth is made are also fundamental for work of greater dimensions. This *plasticity* in the method is such that an operator knowing how to make a single pivot-tooth can without difficulty comprehend the description of how to make a larger denture and can vary and modify it at pleasure to suit each special case. The present chapter on the single pivot-tooth can therefore be said to contain the method *in nuce*. In the description given in the next chapter of a typical piece of work consisting of several teeth, we shall therefore presuppose the knowledge of the numerous details set forth in the next few pages.

First after the root has in all respects been perfectly prepared for receiving a pivot-tooth, the fitting and trying necessary for the adaptation of the pivot-tooth is begun. It is of great importance both for the infallible execution of the operation and for its speedy completion that the root-canal

is antiseptically treated and sufficiently enlarged, and that the cervical end of the root is correctly ground off before the fitting and trying is begun. If due distinction is not made between these two stages in the course of the treatment,— the preparation of the root and the fitting,—it is very easy to get confused by time-killing exchange of instruments and perplexing "corrections" where nothing needed to be corrected. Here, as elsewhere in our profession, it is necessary to acquire a uniform technical skill, i. e. to let the different manipulations follow each other always in the same order and always to perform each manipulation in the same way. Only with a permanently based "ritual" like this is it possible to discover the extremely fine variations in movement by which certain manipulations can be made either more effective, quicker, or less painful. According to my opinion the greatest operative skill in these fine variations of movement is acquired by carefully storing up small experiences gained through the constant repetition of the same manipulation. Every practitioner knows that the first time a new manipulation is carried out the intended result can be reached, but repetition shows, if not how high a degree of perfection can finally be reached, at least how far from perfection the first attempt was. There is a certain similarity between the practitioner who, by storing up small experiences, develops an operation originally executed in a primitive manner into unrecognisable perfection and the pianist who studies and practises a difficult piece of

music till he has fully mastered it. Between the literally correct, slow, and attentive reading of the notes on first seeing the piece of music and its execution in the concert-hall there lies a long period of work which has entirely transformed the piece. The musician follows the notes, to be sure, the first time as well as the last time the piece is played, but by patient and constant practice, he has acquired such a mastery over its details that he has perfected its original form beyond recognition.

The Fitting of the Pivot.

The wire that is used for the pivot is made of platinum with an admixture of iridium to make it harder, for which purpose it should also be condensed by means of a draw plate.

The wire should be of different thicknesses, according to the width of the root-canal which, in its turn, should be modified according to the thickness of the root. Three different sizes of wire ought to be sufficient, —a very thich size, 2—3 mm., a medium size, 1.5 mm., and a small size, 1 mm. To find out which size of wire should be used, the operator should try to insert the end of the wire into the opening of the root-canal; if it is just possible to insert the wire into the opening, the size is correctly chosen. Then the wire is filed off, if possible, to the same elongated, truncate cone-shape as that of the root-trimmer last used in the preparation of the canal. No special circumstantial method for gaining "absolute exactness" is necessary. No very great skill is required to form a pivot by means of a few strokes of the file so that it will go all the way up to the filling in the root-apex and fit to the walls so accurately that it will not wabble (compare Fig. 5). In the exceptional cases where the canal is not round, or where it is extraordinarily wide or shallow, the task is obviously somewhat more difficult. In order

to facilitate fitting in such cases, a little cochineal-solution or articulating-paste can be laid with a brush on the walls of the canal. On inserting the pivot and pulling it out again, red spots will appear at the points where it touches against the walls of the canal. A slight stroke of the file on each of these points and a new insertion will give the desired result. It is clear that when the canal is not regularly conical or cylindrical, care should be taken to insert the pivot every time in exactly the same position, neither turning it nor inserting it crookedly.

In extraordinarily wide canals, the following is the course of operation. The canal is either cone-shaped all the way to the bottom or only the opening is very wide and the apical part of normal shape. In this latter case, it can frequently be sufficient to file off the point of the pivot to fit the apical part of the canal and surround its other end with metal in a manner described further on. It is hereby possible to make a pivot which does not wabble without being obliged to use wire of the large dimensions of the mouth of the canal.

If the root is so much decayed that, instead of a canal, there is only a crater-shaped opening, the following method may be followed. A wooden plug is cut to the same shape as the pivot generally has This plug is inserted into the crater-shaped opening and is held fast in the proper position while amalgam is packed around it. After this amalgam has hardened, the wooden plug is taken out the next day, and in the cavity left after it a platinum pivot is fitted in

the usual manner. At the same time that the amalgam gives a solid support to the pivot, it also acts as a kind of root-reinforcement, receiving the pressure which is otherwise brought to bear on the walls of the root-canal.

After one end of a piece of platinum wire has been in the above described manner fitted into the root-canal, it is cut off at a distance of about 3 mm. from the opening of the canal and the protruding end is bent about 25° in a palatinal or lingual direction. It often happens that, later on when the tooth is tried on, it is discovered that the protruding end of the pivot is in the way. In that case, a groove must be excavated in the root at right angles with the canal, and into this groove the protruding end of the pivot is bent. It should here be pointed out that in grinding the porcelain tooth it is supplied at the back with a groove in order to avoid this collision.

Riegner advises the enlargement of the root-canal in a palatinal direction, in order to avoid this collision, whereby the pivot is given a certain inclination in that direction. The reader will, however, easily see how badly such a proceedure agrees with our demand for the tight fitting of the pivot to the walls. The buccal interstice between the pivot and the wall is, according to Riegner's method, afterwards filled with some kind of binding-substance which will thus support quite a considerable articulating pressure. Furthermore, it cannot very well be denied that the said enlargement of the root-canal, at least to a certain extent, unnecessarily weakens the root.

The Fitting of the Porcelain Facing.

When a porcelain crown is to be ground to fit the root, it ought, in most cases, to be done without the use of a model. The instantaneous and absolutely correct fitting of the crown to the labial margins of the root, which is absolutely necessary in work of this kind, is most easily reached by direct trials after each grinding. Only in case of several crowns standing beside each other, can it be considered suitable to do the preliminary fitting and grinding of the porcelain fronts with the aid of a little plaster model, only making the final adjustment to the mouth itself. Without ascertaining that the teeth are of the right width and determining their position one to another by means of such a preliminary fitting, it may sometimes be difficult to find a fully harmonious set of teeth.

It is also in certain cases advantageous to choose the crown to be used at the very beginning of the work, not only to ascertain that you have a suitable one in stock, but to avoid the unpleasantness and disadvantage of hunting for a suitable crown in a moment when several different manipulations are to follow each other closely. For dentists who colour the teeth themselves, it is absolutely necessary to have this work done before the final fitting. It is therefore to be considered a good rule to choose a suitable crown as soon as possible. After it has been ground

to fit the root, the above-mentioned groove for receiving the protruding end of the pivot is ground out in its posterior surface by means of a little gem or carborundum wheel. It is furthermore advisable to bend the small pins of the crown upwards and outwards, partly to prevent them from colliding with the root-pivot and partly to facilitate the holding of the tooth in grinding and afterwards in putting it in place.

How to make the Porcelain Facing and the Pivot. (Impression).

After the pivot and the crown have been fitted to the root and to each other, we proceed to unite them and to take an impression of the root.

For this purpose the operator should grasp the thickest end of the pivot with the pivot-tooth pliers and warm it over a spirit-lamp. A suitably large pellet of an impression-composition especially manufactured by me for this purpose is then caused to adhere to the pivot by means of heat. This composition, which is to be had at all dental depots under the name of "Samsioe's Impression Composition for Plateless Dentures," is plastic, hardens quickly, adheres very firmly both to the porcelain tooth and to the metal, and does not change volume or form either in or after cooling. After the pivot and composition have again been slightly warmed, the pivot is pushed into the root-canal as far as possible, whereby a perfectly true impression of the root is procured (compare Fig. 6). If it proves to be difficult to take out, a portion of the composition which has possibly fastened on the part of the pivot which has been inserted into the root can be scraped off with a knife.

Then one of the small pins of the porcelain tooth which are bent towards the cutting edge is

grasped with a pair of pliers, and the tooth is warmed over a spirit-lamp sufficiently for the operator to be able to press away the labial margin of the composition with a slight pressure of the tooth and at the same time, by melting it into the composition, secure the tooth in its right position in relation to the pivot and the other teeth in the row (compare Fig. 8). With a little practice, it will be possible to secure the crown in its right position the first time trying. In so doing, great care should be taken that the tooth, presupposing correct grinding, lies close to the root without any composition coming between. If, however, it should appear when the crown is removed that the position was not quite correct in every particular, one can, after renewed insertion, warm up the crown with a warm instrument, and then, with a light pressure of the fingers adjust it into the right position.

In cases where the cervical end of the root-canal is decayed deep, and is therefore very wide, a little pellet of the composition must be laid not only around the protruding end of the pivot, but also so high up on the pivot that a correct impression is made of the enlarged part of the root-canal.

How to cast the Backing from the Impression.

The now fitted parts are invested in a little cast of plaster without admixture of sand, or the like (compare Fig. 9). Before the plaster has entirely hardened, it is cut into a parallelopiped or cube. Besides this cutting, enough of the upper surface of the plaster is removed to leave the crown free a couple of millimetres below the cutting-edge, so that it may afterwards be easily taken up out of the plaster. The impression-composition is warmed up in hot water to a temperature of about 45° Cent. If the composition has been warmed up too much, it will be liable to stick to the plaster and will be difficult to remove without the use of chloroform or ether. If the composition is suitably warmed, however, it is possible successively to take up the crown, the pivot, and the composition, without injuring the plaster or leaving any composition in the mould. The crown and the pivot are scraped clean, and the small pins of the crown are bent and roughend as in ordinary rubber-work, but so that they neither collide with the pivot or with the plaster nor come so high that they can stand in the way in a later articulation.

When the crown and pivot are again in their right place, both the platina-iridium or alloy pivot and the pins are wet with a fine brush dipped in the soldering-acid, care being taken that no acid touches the porcelain tooth or the plaster.

Over the opening of this depression, a couple of pieces of the alloy made by me for this purpose are laid. This metal, which consists of tin, silver, gold, and platinum, in suitable proportions to make it melt readily and solder well, to make it tough, hard, durable, and capable of resisting the acids of the mouth, is to be had at the dental depots under the name of "Samsioe's Metal for Plateless Dentures." The piece of work is placed on a coarse wire-net over a spirit-lamp, or a Bunsen or Fletcher burner. In about ten minutes, according to the size of the plaster ball and the strength of the flame, the metal begins to melt. With a large and strong pair of tweezers, the piece of work is then lifted from the net, is knocked carefully (so that the tooth will not jump out) against something hard, so that the metal is forced down into the cavity of the plaster and surrounds the platinum pins. To make still more sure, the metal is pressed with a little piece of spunk down into the cavity, and at the same time, just before the moment of hardening, the superfluous metal is wiped away, or it is forced up towards the cutting-edge in order to form a chewing-cusp. In cases where an impression of a part of the root-canal has also been made, great care must be taken in moving down the metal. If it is found that too little metal has been used, a little piece may be added to the melted mass, whose heat is frequently great enough to melt the added metal.

After the piece of work has cooled, the plaster is split, and the finished tooth is taken out and subsubjected to a preliminary polishing.

Insertion of the Pivot-tooth.

A pivot-tooth made in the manner described above generally fits so correctly that it only needs to be polished before it is inserted. If it should be observed that any of the metal is in the way, ascertain first if the cervical margin of the crown is correctly filed. Then a little piece of thin carbon-paper can be pressed down over the pivot, a hole being first made in the paper through which to pass the pivot. In this way, it is an easy matter to discover the place that binds. There might have been a little air-hole in the plaster into which the metal ran, or the sharp edge around the mouth of the root-canal might have been injured in the plaster, so that a little metal collected around the insertion-point of the pivot.

When the tooth has come into its proper position, the articulation is examined. Guided by the carbon-paper, the metal or the porcelain front is filed or trimmed or ground off enough to make the teeth bite together correctly. Thereafter, the metal is polished first with sand-paper, its palatinal surface being given a soft and naturally rounded contour, and then with a steel burnisher which is lightly passed over it till it is given an even platinum gloss.

Before the tooth is tried in again, the pivot should be rendered rugged by making scratches or

small barbs all over its surface with a flat graving-tool. Since the pivot has already been accurately shaped to fit the root-canal, these barbs should be made very small. If it should prove to be impossible to insert the pivot after the barbs are made in it, they should be filed off a little. After the pivot-tooth has been secured so that it does not wabble in the least, a couple of incisions, or undercuts, are made with a fine wheel-bur in the walls of the root-canal. As a precaution, it is best to try in the tooth again after this, in order to be assured that it does not wabble, even after this last manipulation. We must lay special stress upon the importance of the purely mechanical stability of the tooth in the root-canal as a factor of its future durability. It can, to be sure, be very easy to make a tooth sit firmly with cement, but both a theoretical view of the matter and experience compels us to sanction the rule: "build as little as possible on the binding-element."

Binding Element.

The binding-elements which we have used for making a *hermetic* connection between the pivot-tooth and the root are cement and guttapercha.

The cement is stirred thick or thin, according to its specific properties, and a small quantity of it is laid around the pivot, but without covering its point. By means of the tumb and index-finger, the tooth is slowly pushed into the canal, being given slight lateral turns in so doing. Superfluous, protruding cement is removed, and when the cement can be regarded as hard enough to withstand the saliva, the work is finished.

For insertion with guttapercha, a little, thin pellet of white guttapercha is passed over the pivot up to the base of the tooth. Then a narrow strip of warmed, red guttapercha is wound around the somewhat heated pivot but may not cover the point and should not extend further down on the pivot than to its middle. After this, the whole piece of work is heated in a heating apparatus which I have constructed for this purpose. If such an apparatus is not to be had, the work may be heated on a sheet of ordinary mica. In so doing, it is necessary to stop the heating before the red guttapercha begins to bubble. The work is then lifted up with a pair of tweezers, is grasped between the thumb and index-

finger, with a napkin as a protection against the heat, and is pressed firmly into position. The white guttapercha around the cervical margin may possibly be squeezed out a little when the tooth is pushed into place. The protruding guttapercha is cut away with a sharp, somewhat warmed knife, and the edge is polished with chloroform on cotton, after which the work is finished.

In ordinary cases, there is nothing to change after the tooth has been inserted. In order to be perfectly sure, however, the articulation should be examined, the appearance criticised, care taken to see that the seam is filled and smooth, and, especially, that none of the binding-element has become hidden under the gingiva. It is not advisable to grind a tooth fastened with cement before it has perfectly hardened.

It is hardly necessary to point out that the canal must be kept dry while the tooth is being inserted, for instance by means of a napkin and by blowing warm air on it.

The advantages of cement is securing pivot-teeth are principally the following: that it is not necessary to use much more force than in trying them in, which fact may be of importance to sensitive patients, and that it is a very easy matter to press out the surplus of cement with the pivot and then remove it. The disadvantages which accompany the use of cement as binding-element are somewhat more subtile but none the less serious. Cement is known not to be very reliable. In some mouths it will barely

hold at all, in others it becomes porous or is dissolved, without its being possible to say beforehand which will be the case. Cement is brittle, and can be crushed by a single stroke, so that the fluids of the mouth are sucked up into the interstices by capillary suction and have an opportunity of exercising their destructive influence. Furthermore the whole piece of work is endangered if a tooth is secured by cement in a root which proves not to be fully reliable. Thus also in repairs or alterations it is time-killing and troublesome to remove a tooth which has been secured by cement. Some maintain that in roots with very thin walls cement has the advantage over guttapercha that it can be mixed so thin that no pressure is necessary in inserting the tooth, thus removing every danger of splitting the root. The superiority of cement is, however, much lessened by the fact that the use of the above-mentioned heating apparatus enables the operator to give the guttapercha such a consistancy that any root that can bear a pivot-tooth can stand the pressure required for insertion. I maintain that a root supporting a pivot-tooth under certain conditions of articulation and under the effect of outer violence, is strained much more than when the binding-element has a certain elasticity which makes the transmission of pressure to the root much milder. In strong roots, this pressure does not, of course, play anywhere near the same part as in roots with thin walls.

The advantages which guttapercha has as binding-element depend partly on its small, I might even

say minimum, susceptibility to attacks of the fluids of the mouth, partly on its elasticity, and partly on its property of becoming soft when warm. I dare say that if the fine interstice between the tooth and the root is filled with guttapercha and carefully polished, the root may be considered to be perfectly protected against caries. And I am not alone in this good opinion of guttapercha as a protection of the root in pivot-tooth work.

The protection afforded by guttapercha to weak roots, on account of its elasticity, has already been mentioned. I can also point out the fact that, in exceptional cases, when the pivot on insertion still wabbles a little in the canal, the tooth can be more securely fastened with guttapercha than with cement, for it will stand both an accidental blow and the repeated pressure of chewing without either being dislocated or changed, since it is tough and elastic.

Guttapercha has furthermore the advantage that it becomes soft on being warmed sufficiently, and allows the tooth to be removed from the root without any trouble. The importance of such removable crown-work is obvious. Repairs and other extensive alterations in crown-work which has, perhaps, been worn for a long time, cannot, in many cases, be accomplished as long as the work remains in the mouth, and can, at all events, be done much better when the work is removed.

The advantages of using white guttapercha at the cervical margin consist partly in the possibility of easily cutting away any protruding mass without

danger of extenuating it, as is the case in red guttapercha, thereby disturbing the hermetic junction, and partly in the fact that the white seam is not so conspicuous if it should happen to be exposed. The red guttapercha, on the other hand, has the advantage that it adheres tightly to the pivot and to the walls of the root-canal, that it is tougher, and that it becomes softer on being warmed up than the white.

Crown secured to the root of an adjacent tooth.

After having followed the making and putting in of a pivot-tooth through all its different stages, we will now proceed to describe the making and putting in of a pivot-tooth secured to the root of an adjacent tooth. This must be resorted to when there is no root where the pivot-tooth is to be placed or the root is not fit for supporting a pivot-tooth, while the adjacent tooth still has its crown. If the root is still intact, the danger of the periostal affections to which, in course of time, it may be exposed should be carefully considered before it is decided to make it inaccessible by covering it with a pivot-tooth. In case the patient has not time to wait for the gums to heal after extraction, and it is possible to protect the root against new infection by means of an antiseptic application at the apex and a permanent filling at the cervical end, it is not necessary to extract it. If, however, the root is of such a nature that it cannot be filled, the best plan is to extract it and postpone the insertion of the new tooth till the gums are entirely healed. If the patient cannot get along without the tooth in the meantime, a temporary rubber plate is suggested. Let us suppose that the gingiva has its proper consistency at the place where the new pivot-tooth is to be placed, that the adjacent tooth which is to

support the pivot-tooth is filled at the apex of the root with an antiseptic filling, its canal enlarged, and an opening made in the crown towards the defect. The pivot is fitted as described above, and is bent at right angles before it is cut off. The porcelain tooth is ground, and it is ascertained that it does not collide with the pivot. If this should be the case, the pivot should be bent in a palatinal direction, so that the crown can come in its right place. Then the pivot and the tooth are connected *in situ*

Fig. 1.

(see Fig. 1) by means of a pellet of impression-composition after both have been rendered adherent by melting a little composition on them. The work is taken out, invested in plaster, and is cleaned from the composition, after which the pivot is carefully bent so that it will come into contact with the somewhat flattened pins in the porcelain crown. Then the pivot and the crown are united by gold-soldering. After the work has cooled and has been boiled in nitric acid, it is again tried in. A little pellet of wax is placed behind the porcelain tooth and is pressed up against the gum and forward behind the adjacent tooth which is not to support the pivot. The work is taken out, and the wax is cut to the form afterwards to be given the metal, and then it is fitted in again. The work is invested in

plaster, the wax is removed, and the metal is caused to melt and run down into the little cavity in the plaster, as in making the above-described pivot-tooth. When the metal is pressed with a piece of spunk, great care should be taken to see that the retaining extention behind the adjacent tooth which was impressed in wax gets its proper shape. In fitting this work, it must be observed that it is not clumsy, and that the retaining extention is given such a form that it can fill its office without being unpleasant to the tongue or interfering with the articulation. The object of this retaining extention is

Fig. 2.

partly to prevent rotation of the piece in relation to the supporting tooth and of this tooth itself. The retaining extention does not need to be large in order to answer this purpose. It is frequently sufficient if it extends a little way beyond the approximal-palatinal corner of the supporting tooth. It is of great importance that it fits tight to the retaining

tooth (see Figs. 2 and 3, before and after the insertion of 3 + attached to 4 +).*

It might be the case that this point had a predisposition for caries, and therefore it should be given special attention at the annual inspection, which should never be neglected. The advantages of this retaining extention are so great that the exceptional appearance of caries should not deter the dentist from making use of it.

Fig. 3.

After the articulation has been arranged, the piece polished, the pivot furnished with scratches or barbs, and undercuts have been made in the root-

* According to a method of nomenclature invented by Dr. Haderup of Copenhagen, a + is supposed to be placed between the two middle teeth in the upper jaw and a — between the two middle teeth in the lower jaw, all figures placed to the right of the respective sign referring to the teeth in the left side of the jaw and the figures on the left of the sign to the teeth on the right side of the jaw.

canal, the piece is put into place. It should here be remarked that this kind of pivot-tooth, as well as other kinds, must sit mechanically solid in the root-canal before it is secured by means of the binding-element. The cavity in the pivot-supporting tooth is filled, after the insertion of the pivot-tooth, with amalgam or gold.

A tooth like this should, according to my opinion, never be fastened by cement. The advantage which cement has in other cases on account of the surplus being easy to wipe away, does not play any part here, since a surplus of guttapercha can easily be removed from the cavity. Besides, in using cement, there is danger of a frequently almost inaccessible cervical caries at the point where the pivot enters the tooth. Even if the pivot is bent down to the cervical margin of the retaining tooth, as should be the case, there is a capillary interstice which it is preferable to fill with guttapercha instead of cement. As soon as the usual corrections have been made after the insertion of the tooth and the amalgam filling has been polished, the work is finished.

In inserting a similar tooth in an under jaw with a normal bite, the retaining extention is unnecessary. In order to counteract the inward pressure to which such a pivot-tooth is subjected, it is advisable, instead, to grind the porcelain front a little thinner on the margin nearest the adjacent tooth not supporting the pivot, letting it rest on the approximal-labial corner of this adjacent tooth.

CHAPTER V.

Detailed specification of a large, special piece of work.

In order to give an idea of the way in which a piece of work consisting of several teeth without plate can be made, I shall in this chapter specify from beginning to end the different manipulations which are required for putting in four connected crowns attached to two roots.

The case which we choose is a defect in the crown of the left cuspid of the upper jaw, the absence of the whole lateral and central incisor and a defect in the crown of the right central incisor. (Fig. 4.)

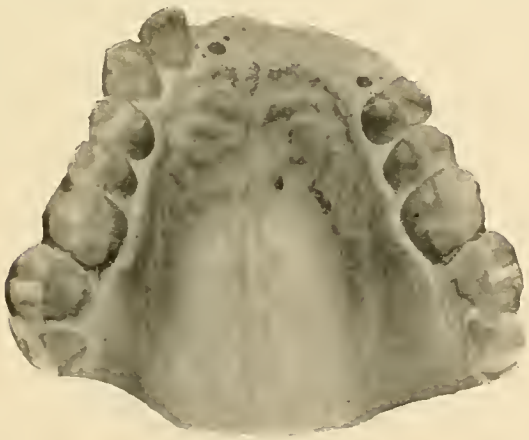

Fig. 4.

As may be seen, this work was, for the sake of the illustrations, done on plaster models taken from the intermediate stages. All the other pieces of work represented in this book were done on patients, and the figures were taken from models of patients' mouths.

Thus, for securing the denture, we have at our disposition two strong roots, one of the left cuspid and the other of the right central incisor. These roots, whose canals run somewhere near parallel to each other, have been cleansed, furnished with antiseptic fillings at the apex, and ground down below the gingiva.

The end of a platina-iridium wire of the proper thickness is filed to fit into each root-canal, so that, when inserted to the very bottom of the root-canal, it will not wabble. A couple of millimetres outside the cervical opening of the root-canal, the wire is cut off, and its protruding end is bent to an angle of about 45° in a palatinal direction (Fig. 5).

Fig. 5.

The teeth which have been chosen are ground direct after the mouth, care being taken that no interstices are left between them, and that their cervical ends are caused to stand so close together that the metal will not be visible. As support for the teeth while trying them in, a little wax plate shaped after the mouth can be used. It is also suitable, even at this stage, to bend the small platina pins in the tooth about 45° towards the cutting-edge. The teeth will thereby be easier to hold and manipulate. On the two teeth which are to be placed on the pivot-bearing roots, a groove is made on the palatinal side between the bent pins in order to prevent collision with the platinum pivot.

The pivots are in turn warmed, furnished with impression-composition, and inserted into the root in order to get an impression (Fig. 6). These two small

Fig. 6.

impressions are taken out and the impression-composition which has worked up round the pivot in the canal is scraped off with a knife in order to make the impression easy to remove, and the impressions are then connected by means of a warmed bar of impression composition, which is very carefully pressed up against the gingiva (Fig. 7). This whole system

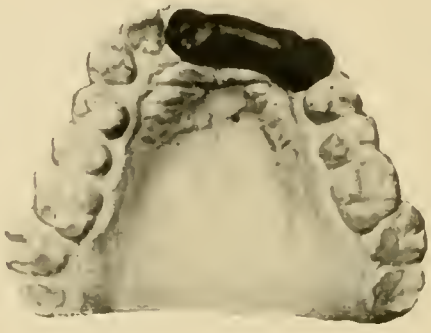

Fig. 7.

is then removed in order to examine its substantial properties and to see that it is easy to remove, after which it is again inserted.

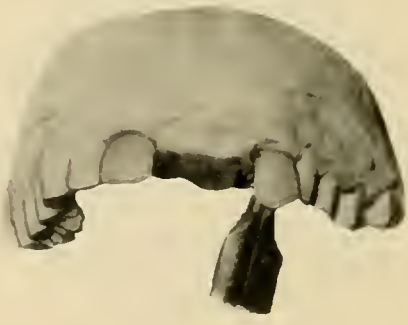

Fig. 8.

With the pivot-tooth pliers one of the bent pins of the right central incisor is grasped, the tooth is warmed and placed with a firm pressure in its right position on the root. The same manipulation is carried out with the cuspid, care being taken to press it firmly up against the gingiva and to place it correctly in relation to the adjacent tooth (Fig. 8). The two middle teeth are treated in the same manner.

The whole piece of work is carefully taken out and placed in plaster. Before the plaster has entirely hardened, it is cut so that about a quarter of the crowns will stand out free.

When the plaster has sufficiently hardened, the work is laid in tepid water, which softens the impression-composition and makes it possible to take up the teeth, the pins, and the composition out of the plaster. The platinum pivots and the teeth are scraped clean, after which the pins are bent in a sharp angle backwards and downwards, but so that they will not collide with the platinum pivot. In warming, too high a temperature must be carefully avoided. The water should not be more than 45° Centigrade.

After pivots and teeth have again been placed in their proper position in the plaster impression (Fig. 9), a suitable number of cubes of metal-alloy



Fig. 9.

are laid on top of the impression and the work is heated on a wire netting with large meshes over a gas or spirit lamp. After about ten minutes, the metal begins to melt. When it has entirely melted, the work is lifted from the net with a large and strong pair of pinchers, and is lightly tapped against some hard substance. The metal can then be still more pressed down into the impression by means of a piece of spunk, with which it may also be modelled just before it hardens.

When the work has cooled off, and after the plaster has been broken away, it is subjected to a preparatory polishing before being tried into the mouth. With file, burs and the dental engine, scraper, sandpaper, and polishing-steel, the piece is formed, smoothed, and polished (Fig. 10). Care should be taken that

Fig. 10.

the articulation is correct, and the pivot is supplied with cuts and the root-canal with an undercut. Before securing the work, it must be carefully ascertained that the piece does not wabble in any direction when subjected to pressure. If this should be the case, the wabbling can be prevented by making barbs at suitable points on the pivot.

It is hardly necessary to point out that the roots, during the trying and all the time after the removal of the occlusive bandage, must be kept dry. To make sure of this, a little warm air is blowed into them just before the piece of work is inserted. Securing with guttapercha is done in the following manner: A thin, perforated pellet of white guttapercha is passed on to the pivot, after which it is wound round with red guttapercha (Fig. 11). The

Fig. 11.

work is warmed up in the apparatus constructed by me for this purpose, and is inserted with a sudden, strong pressure. Any protruding guttapercha is cut away with a knife (Figs. 12 and 13).

Fig. 12.

To show how to do, if it is desirable in such a piece of work to unite the pivots and the teeth by

Fig. 13.

means of gold-soldering, I might refer to Fig. 14, which is taken from such a piece of work done by me. The somewhat flattened pins of the porcelain teeth are soldered to a transverse bar of platinum



Fig. 14.

wire which connects the two pivots. An impression is then taken of the roots and gums in wax previously melted on to this gold-soldered work, which is then finished in the aforesaid manner.

CHAPTER VI.

How to make two connected crowns.

In securing two connected crowns, eight different typical cases can occur, depending upon the number and nature of the anchorages. Referring to the above detailed description of how to make a single pivot-tooth and of a piece of work consisting of four teeth, we take it for granted that the general technical principles are already known. Details not yet described will be treated in connection with the cases in which they occur.

The different ways in which two crowns can be secured are as follows: —

I. Two teeth with one pivot in one root.

In a defect consisting of the absence of a whole tooth and the crown of the adjacent tooth, a pivot capable of supporting the two lacking crowns can be secured in the root.

The way in which this is done somewhat reminds one of the way in which *one* crown is secured to the root of an adjacent tooth. The protruding end of the pivot is left so long that it can run

along behind both of the teeth, and it is bent so low down that collision with the nearest crown is avoided. With the protruding end turned in a lingual direction, the pivot is inserted with impression-composition, and the crown belonging to it is secured in the usual manner. Then stick to the impression thus received a piece of impression-composition, to which the other crown is secured in its right position in relation to the gingiva and the teeth. The work is removed and laid in plaster for gold-soldering. After the impression-composition has been cleared away, the pivot is turned and its protruding end is bent so that it will lie quite near the gingiva, close behind the crowns and under their flattened pins. In this position the pivot and the crowns are soldered together in one piece.

With an impression like this, it is, of course, not necessary to strive after any accuracy with respect to the basal part, but only in regard to the position of the crowns and pivot. First after the soldering, the wax is melted on to the pivot behind the crowns, and an impression is made of the end of the root, gingiva, and the back of the retaining adjacent tooth. The work is invested in plaster, the wax is washed off and the metal is melted over the impression. After polishing (Fig. 15), special atten-

Fig. 15.

tion being given to the retaining extension, the work is inserted in the usual manner with cement or gutta-percha, depending upon circumstances.

In certain cases of specially favourable articulation, soldering with gold can be considered unnecessary. In such instances, the first impression with the hard impression-composition must be made perfectly correct. The protruding end of the pivot does not then need to extend behind both the crowns in order to be solidly fixed in the metal.

II. Two teeth with two pivots each in its root.

When there are two roots situated beside each other which are to be supplied with crowns, the teeth should, if possible, be isolated, or secured independent of each other.

As a rule, all pieces of work like this should be divided into as many sections as possible, partly in order to imitate nature as much as possible, and partly because the work is hereby rendered easier to do and the denture is easier to repair. For instance, when two roots greatly diverge from each other, it is impossible to give two connected pivots the same length as two separate ones.

It sometimes happens, however, that one of the roots or both of them are too short, too much decayed, or too loose, to support a tooth each by itself, while by supplying them both with pivots connected with each other, sufficient stability may be obtained.

After the ends of the roots have been ground down below the gums in the manner before described, an impression of the defect may be taken if it is considered necessary. For this impression, which is chiefly taken in order to determine the width of the crowns, it is generally not necessary to make use of any impression-tray, the fingers being used instead, and a suitably large and hard piece of Stent's composition being pressed up. While the plaster is hardening, the preparation of the root-canals and the trying in of pivots may be carried on in order to save time. With the guidance of the model, suitable crowns are chosen and ground to fit on to the roots.

By means of impression-composition, each pivot is connected to its respective crown, the same as in making two separate pivot-teeth. Care should be taken that the two teeth are so made and secured that they are easy to take out, each by itself, after which they are connected by pressing a very warm pellet of impression-composition about the size of a pea against the composition already present. Then the piece is taken out whole.

One of the special advantages of my impression-composition is that when sufficiently warmed up over a spirit-lamp, it will stick to composition which has already cooled, and that, after cooling, it does not shrink in the least. One can be perfectly certain of the correctness of a whole removed piece of work, since the composition will break rather than bend or be dislocated in any way. Thus it is

possible to discover any fault at an early stage of the operation while it is easy to be remedied, instead of being unpleasantly surprised by the discovery of the fault after the work is done.

The completion of a similar piece of work (Fig. 16, two mesial incisors in the lower jaw) is done on the pattern of the above-described piece of work on four teeth.

Fig. 16

In Fig. 17, we see a similar piece of work inserted. The root of + 5 was so decayed that it was hardly strong enough to support a pivot-tooth alone, wherefore its pivot-tooth was connected with the pivot-tooth on the root of + 4.

Fig. 17.

2 +, 1 +, + 1, + 2, + 3 are single pivot-teeth.

III. Two teeth with a pivot in one root and a collar around an adjacent tooth.

This way of fastening two teeth is mostly used in defects of the premolars and of the first molar, if the first or second molar behind it is still intact and there is still a suitable premolar root.

In similar cases, porcelain-facings or teeth with chewing-surfaces may be used as preferred. To make a connection between the pivots, the collar, and the teeth, a piece of platinum-wire is fitted into place and hammered flat at the end turned towards the collar, in order to make a larger soldering-surface.

In making the collar, it should be remembered that its ends should meet at the mesial-lingual corner of the tooth, and that its soldered ends should be made so long that they can be solidly soldered together with the flattened end of the platinum wire. The collar should be soldered before it is tried together with the pivot and teeth.



Fig. 18.

After soldering with gold, try with wax, from which metal is cast in the usual way. Before in-

sertion, a mesial-buccal, crescent-shaped excision may be made in the collar, if it is considered necessary for the sake of appearance.

This work can be secured in different ways, either with cement to both pivot and collar, or with guttapercha around the pivot and cement in the collar. The first way offers no difficulties, while the latter requires considerable speed in execution. While the piece with guttapercha around the pivot is warmed, the cement is stirred. When the guttapercha has become sufficiently warm, the cement is

Fig. 19.

quickly placed around the cervical margin of the collar, and the work is then inserted. The collar can then be pressed around the crown by means of a pair of pliers, before the cement has hardened, whereby its solidity is considerably increased. Com-

Fig. 20.

pare a similar piece of work with two pivots and a collar: Fig. 18 invested in plaster, Fig. 19 soldered with gold, Fig. 20 complete.

IV. Two teeth with a pivot in the adjacent tooth on either side.

When there are no roots to which the teeth can be secured, and when the defect is situated so far in the front of the mouth that the use of a collar around the front tooth cannot be allowed, it is frequently necessary to let the adjacent teeth bear the pivots which are to hold the artificial crowns in place.

It is obvious that the root-canals of the adjacent supporting-teeth must be parallel to each other in order that such a piece of work can be done, and it should not be undertaken without a certainty of a solid and durable result. It cannot generally be considered advisable to attack two sound teeth for this purpose. We should have respect for healthy enamel.

Let us suppose that the defect is in the upper incisors of the right side, and that we therefore intend to secure the denture to the right cuspid and the left central incisor. From the palatinal side of these teeth, free access is got to their root-canals, which are cleaned out, filled, and enlarged in the usual manner, as described above. The protruding ends of the pivots are left indefinitely long on trying

in for the first time and are connected with each other by means of a thick roll of impression-composition. Before the teeth are put in place, it is ascertained if the pivots can be easily removed. The ground teeth are secured in the impression-composition, the work is removed, and the pivots and teeth are united by soldering on a platinum wire. After the work has been tried and fitted with the aid of wax and cast in metal, it is inserted with guttapercha, after which the cavities on the palatinal sides of the supporting-teeth are filled with gold or gold-amalgam.

V. Two teeth secured by a pivot in one of the adjacent teeth and by a retaining extension to the other.

If the aforesaid parallelism between the root-canals of the adjacent teeth does not exist, or if the adjacent tooth cannot bear such a weakening loss of substance as is required for the insertion of a pivot from the lingual side, it is possible to support two teeth by securing a pivot in one adjacent tooth and running a retaining extension to the other. I must say, however, that I have never found such an expedient necessary.

VI. Two teeth with one pivot in a root and another in an adjacent tooth.

This case occurs, for instance, in a defect of the crown of the right cuspid and of the entire

first premolar. A pivot in this cavity is a better fastening than a retaining extension to the adjacent tooth.

VII. Two teeth secured by a collar around one adjacent tooth and by a retaining extension to another.

In Fig. 21, we see such a piece of work inserted

+ 4, + 5 are secured by a collar around + 6. An extension braces against + 3. The decayed crown of + 6 is first covered with a gold cap fastened with cement in order to reinforce it. The work is secured by a collar instead of direct to the gold crown, in order that the work may be easier to remove.

Fig. 21

VIII. Two teeth secured by a collar around one adjacent tooth and by a pivot in the other.

In case a defect in two teeth is situated so far back in the mouth that a collar can be passed around the posterior adjacent tooth and a pivot inserted in the anterior one, the collar is first made ready as in case No. III. and then the pivot as in case No. IV., after which the collar is united to pivot and teeth, in the manner already known. In order to make a fast connection between the pivot and the collar and with the teeth, a gold-soldering as reinforcement is necessary.

CHAPTER VII.

How to make three connected crowns.

In fastening three connected crowns, seven different typical cases can occur, depending upon the number and nature of the fastening-points.

I. Three teeth with two pivots, either beside each other or in the two outer teeth.

In order to make the trying in easier or to facilitate articulation, it may be suitable, after filing the pivots and grinding the crowns, to unite these parts with each other *in situ,* regardless of the basal part of the impression. After investing in plaster and clearing away the impression-composition, a platinum wire, or a transverse bar between the root-pivots, is laid so that it is touched by the somewhat flattened pins of the crowns. The different parts are united by gold-soldering, after which an impression of the basal part of the work is taken in wax, from which the metal is cast in the usual way. It is obvious how much playing-room antagonists will get by this way of doing, since, without decreasing the solidity of the piece,

so much of the metal can now be removed as the articulation requires. It should, however, be ascertained, before wax is laid on, that no part of the platinum-skeleton forms an obstacle for so-called "close bite." It is, namely, as long as the skeleton is naked, easy to correct this without decreasing the strength of the skeleton, while, on the other hand, it would be an easy matter, after the metal was cast on it, to injure the platinum skeleton or some of the pins of the crown. If the roundabout way of making a gold-soldering and a new trying in with wax is not taken, a direct impression can be procured of roots and gingiva, and the teeth can be placed in perfect analogy with the manipulations described in the typical case of four teeth.

Fig. 22 shows a piece of work of this kind, on which 2 +, 1 +, + 1 are secured in one piece to the roots of 2 +, + 1.



Fig. 22.

II. Three teeth with a pivot in one root and a retaining extension.

If three crowns beside each other should be lacking, and there is only one root and the palatinal surfaces of one or both of the adjacent teeth to support a plateless denture, it must be very carefully taken into consideration whether the root is so strong and firmly fixed in the jaw that it can bear the denture and whether the articulation is such that it could bring about a dislocation of the root or of the retaining teeth. For my part, I must dissuade from making such a denture, unless the root is located in the centre of the defect and the articulation can be arranged so that the piece of work is not subjected to a very hard strain.

The execution of such a piece of work does not necessitate any special deviations from the general rule.

III. Three teeth with a pivot in a root and a collar around an adjacent tooth.

When there is only one root, there is greater certainty in running a collar or clasp around the distal adjacent tooth. As the preceding case principally occurs in defects of frontal teeth, this occurs exclusively when the distal tooth is a molar or a premolar. We will not here discuss the running of a collar around frontal teeth or covering them entirely with gold, as is sometimes done.

In executing such a piece of work, care should be taken that the pivot and the sides of the collar are so nearly parallel that the work will not go to pieces on taking it out.

Fig. 23.

Fig. 23 shows such a piece of work inserted. 6 +, 5 +, 4 +, are secured by a collar running around 7 + and by a pivot in the root of 4 +.

The two connected crowns of + 4 and + 5 are secured in a similar manner, according to case No. III. in the preceding chapter, with a pivot in the root of + 4 and with a collar around + 6.

Fig. 24.

(Fig. 24). The preceding piece of work in articulation.

IV. Three teeth with a collar around one adjacent tooth and a pivot in the other.

If both crowns and roots of three teeth beside each other are lacking, a denture can be secured by a collar around the one adjacent tooth and a pivot in the root of the other.

This expedient is chiefly used in defects of the premolars and the first molar, when the cuspid and the second molar are still intact.

The work is done in analogy with case No. VIII. for two teeth, although, instead of securing a collar around the crown, it may be covered, after its sides have been ground parallel, and then a tight-fitting collar may be passed around the gold cap thus made, with a "rider" in the chewing-groove.

V. Three teeth with a pivot in the root of each adjacent tooth.

If a defect of three teeth is situated so far in the front of the mouth that, in securing the work, one of the adjacent teeth cannot be used as collar-bearer, there are certain cases when the denture can be secured by a pivot in the root of each of the adjacent teeth.

If, for instance, the defect consists of the incisors and cuspids of the left side, a denture can, in many cases, be secured to the roots of the right central incisor and the left first premolar. It is, however, more seldom the case that, for instance, the right lateral incisor and the left cuspid have such a position and strength that they are able to bear the three intermediate teeth.

For the sake of solidity, it is advisable to unite the pivot and the artificial teeth with a strong platinum wire by means of gold-soldering.

VI. Three teeth with one pivot in a root and another in the adjacent tooth.

Since the fastening points in this piece of work have only two artificial teeth between them, it is more likely to be durable than the preceding denture, whose length extends over five teeth and whose anchorages are situated at a greater distance from each other.

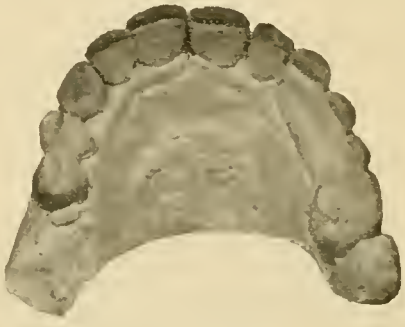

Fig. 25.

We see a piece of work of this kind in Fig. 25, where $+3$, $+4$, $+5$, are secured in one piece to $+3$ and $+6$. The fastening in $+6$ consists of a pivot secured in the palatinal root. The cavity is afterwards filled with red guttapercha, wherefore the work can easily be removed. $4+$, $2+$, $1+$, $+1$, $+2$, are single pivot-teeth. In the model a mark is visible after the suction-chamber of a formerly used rubber plate.

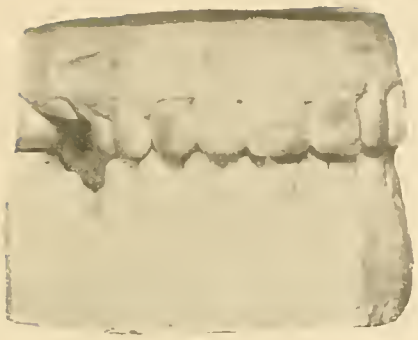

Fig. 26.

(Fig. 26). The preceding piece of work in articulation.

VII. Cap with Socket.

In some cases when a collar seems to be the most fit support of a piece of work of this kind, it may be suitable, on account of the position of the retaining tooth, to furnish the cap which covers it with a square socket soldered fast to it, in which a short, stout, and carefully fitted pivot can be inserted. If this pivot is fastened with guttapercha, the work will, besides, be easier to remove than if we secure it with a collar, which, perhaps, would have to be fastened with cement.

CHAPTER VIII.

Specification of how to insert a larger number of teeth.

I hope that I have made the descriptions of one, two, and three teeth so plain and exhaustive that a piece of work consisting of a larger number of teeth could easily be executed by following these descriptions. I therefore do not think it necessary to describe similar but larger pieces of work in detail, but will only give some general advice. For that matter, the figures in this chapter will doubtless speak plainly enough for themselves. Of the great number of dentures of this kind which I have made in the course of several years, I have chosen only these models, since I believe that they are enough to illustrate my method and my way of putting it into practice.

Several years ago I began to take impressions of the mouths of my patients after inserting these dentures, because in the report of an annual dental congress at which similar work had been discussed I saw that a member of the congress had expressed the opinion that it was easy to draw such a piece of work on paper or to execute it on a plaster

model, but it would be very difficult to execute it in the mouth of a patient. I have, therefore, in some cases, taken an impression both before and after insertion, and, furthermore, showed the articulation. Since the impressions are photographed, they are necessarily true copies of the originals.

After this little digression, I will return to the subject. On inserting a larger denture, we must, if possible, with still greater care than in inserting a small denture, pay attention to the reasons *pro* and *con*. I will, therefore, mention a few things which a dentist should take into consideration before deciding to undertake such a piece of work.

In the first place, we must think of the number of roots, of the roots themselves, and of their firmness in the alveole. The more roots we have at our disposition, the better; this will allow the work to be divided into all the more small pieces, an advantage which was pointed out already on page 107. The roots which are used as supports must be strong, not too much decayed, and freed from eventual affections, and must be firmly fixed in the alveole If there are only a small number of roots, we must look about for other possible anchorages.

Another important thing, which we must take into consideration on examining the mouth of a patient, is the articulation. The more natural teeth biting together, and the firmer and stronger these are, the better.

The age of the patient also plays a part, but not so great as I once saw stated in literature, the

author in question being of the opinion that a pivot-tooth should not be put in the mouth of a patient over forty years old. We all know how firmly teeth sometimes sit in the alveole even of patients of a very considerable age. I might mention, by way of illustration, that I once put in a pivot-tooth for a lady who was 85 years old.

It must also be remembered that it is sometimes necessary to take into consideration whether the patient lives in a place where there is a dentist. It is frequently sufficient to send a broken plate to be repaired, but if there is anything the matter with a bridgework, the patient must come himself.

Fig. 27.

(Fig. 27). 3 +, 2 +, 1 +, + 1, + 2, are all single pivot-teeth.

Fig. 28.

(Fig. 28). The six front teeth are all single pivot-teeth.

Fig. 29.

(Fig. 29). 3 +, 2 +, 1 +, + 1, are secured together to the roots of 1 + and + 1.

+ 2 single pivot-tooth.

Fig. 30.

(Fig. 30). 4 + is connected with 2 + by means of a platinum wire lying behind 3 + and running to a piece secured to the root of 2 +.

Fig. 31.

(Fig. 31). 2 +, 1 + are secured together to the roots of 2 + & 1 +. One of the roots was very much decayed. + 1, + 2, + 3, + 4, are secured in one piece to the roots of + 1 & + 2.



Fig. 32.

Fig. 32 shows a piece of work in which 4 +, 3 +, 2 +, are secured in one piece to the roots of 3 + & 2 +. The natural tooth 5 + is palatinally dislocated, wherefore the crown of 4 + appears to be

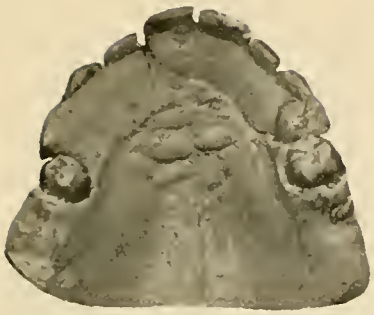

Fig. 33.

protruding but in reality this is not the case. Furthermore, we can see the roots of 1 +, + 1, which are used as supports for the crowns of 1 +, + 1, + 2, + 3 in Fig. 33. On the same piece there is placed a retaining extension behind + 4 by way of reinforcement in articulation. The patient had used a rubber plate for nine years. The crown of 3 + had however, only been substituted two years before. When I was consulted, I advised the removal of the crowns of 1 +, + 1, which were very much decayed.

Fig. 34.

(Fig. 34). A defect of the crowns of 5 +, 4 +, 3 +, 2 +, 1 +, + 1, + 2. The roots of 5 + & 4 + are extracted.

Fig. 35.

Fig. 35 shows the way in which the defect was substituted. 5 +, 4 +, 3 +, 2 +, are secured in one piece to the roots of 3 + & 2 +. On the three other roots there are single pivot-teeth.

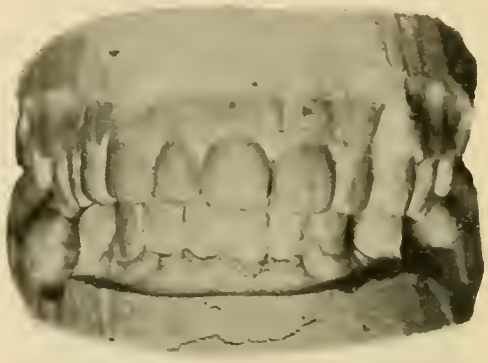

Fig. 36.

(Fig. 36). The preceeding piece of work in articulation.

Fig. 37.

(Fig. 37). 4 + 3 +, 2 +, are secured in one piece in the roots of 4 +, and 2 +. 1 +, + 1 + 2, are single pivot-teeth.

Fig. 38.

(Fig. 38). 5 +, 4 +, 3 +, 2 +, 1 +, +1,

are secured in one piece in the roots of 4 + and + 1. + 2 and + 3 are secured in one piece in their respective roots, since the root of + 2 was bad.

Fig. 39.

(Fig. 39). The eight front teeth are secured in two separate pieces to the roots of 3 +, 1 +, + 1, + 3. The patient has formerly used a rubber plate for twelve years, and during this time felt very much annoyed by it.



Fig. 40.

(Fig. 40). Impression taken of the same mouth five years after the insertion of the preceding piece of work.

We can see how very slightly the work has changed. Notwithstanding that these teeth have been exclusively used for chewing, and all the biting was done on them, there is only a very slight wear of the metal in the vicinity of 4 + & 3 +. The intermediate space between 1 + & + 1 has, besides, become a little larger.

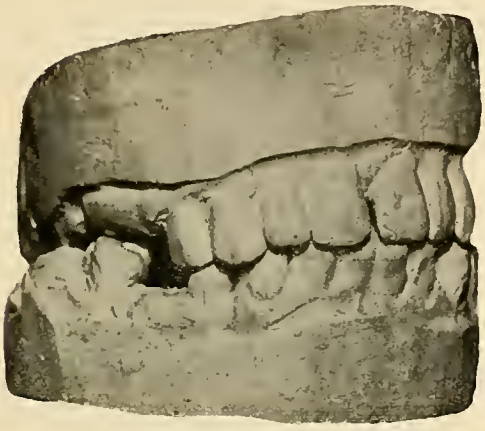

Fig. 41.

(Fig. 41). The preceding piece of work in articulation.



Fig. 42.

Fig. 42 shows an impression taken when the patient first came to me, four and a half years ago. She had, in the course of several years, had several rubber plates, made by different dentists, but had in every case been dissatisfied with their work. Since I had no reason to believe that I could make a plate

Fig. 43.

any better than my colleagues, I complied with the wish of the patient and did the work shown in Fig. 43. The eight front teeth have since then been held fast by 3 + & + 3. The backing looks wider in the photo than it was in reality, probably because the photographer did not succeed in getting a good profile on it.

Fig. 44.

(Fig. 44). 5 —, 3 —, — 5 are secured each to its root.

— 4 consists of a porcelain front fixed by a pivot to the root. The inner edge of the natural tooth, which was strong, is retained. The intermediate cavity is filled with amalgam. The insertion of the premolars presented rather great difficulties, since the crowns had to be made very low.

Fig. 45.

(Fig. 45). 5 —, 4 —, secured in one piece to the roots of 5 —, 4 —.

The root of 5 — was bad, wherefore I preferred to fasten 5 — to 4 — instead of putting it on its own root.

— 3, — 4, — 5, are secured to the roots of — 3, — 5.

Fig. 46

(Fig. 46). 4 —, 3 —, 2 —, 1 —, — 1, — 2, secured each to its root. Some authors, to be sure, regard the insertion of pivot-teeth in the front roots of the lower jaw as an impossibility, but this is by no means the case.

Fig. 47.

(Fig. 47). 4 —, 3 — secured in one piece to the roots of 4 —, 3 —.

2 —, 1 —, — 1, — 2, secured to the roots of 2 —, — 2.

— 3, — 4, — 5, secured to the roots of — 3, — 5.

Fig. 48.

(Fig. 48). The preceding piece of work seen from the front.

CHAPTER IX.

Comparison with Witzel's Method.

In his great work *Compendium der Pathologie und Therapie der Pulpakrankheiten des Zahnes*, Dr. Witzel has given a detailed description of his method of making isolated pivot-teeth. Since this method has succeeded in gaining a greater popularity in Scandinavia than any other pivot-tooth method, a more careful comparison between it and the principles upon which the method described in the preceding chapter is founded may not be out of place here.

The great value which Witzel himself ascribes to his principles appears clearly from his own words in § 319 in his book. "A flat tooth furnished with a fine gold plate covering the whole back of the tooth and soldered fast to a root-plate carefully fitted to the root-surface can in all respects be considered as the most perfect substitution of teeth." I suppose that the author has understood that the "root-plate" should also be soldered fast to a pivot, in order that this excellent apparatus should be perfectly practicable.

On more carefully examining the way in which such a pivot-tooth is made, and how it fills the de-

mands which can nowadays be placed on such a piece of work, one is certainly somewhat surprised at the confident addition made by the author; and considering that such an eminent practitioner as Dr. Witzel feels so highly satisfied with a method which, however, in certain points, does not fill all due demands, everyone who has recognised these deficiencies should gladly greet new improvements which are intended to remedy these deficiencies.

In Witzel's method, we do not get further than the enlargement of the root-canal before we are exposed to such a fatal inconvenience as the perforation of the wall of the canal. The simple cause of this is that a cylindrical drill is used instead of an elongated conical bur. The higher up we go in the canal with a bur with a small diameter at the point, the less the canal is enlarged at the upper end, and the danger of perforation is, consequently, all the less. A cylindrical drill, on the contrary, whose point is about the diameter of the opening of the root-canal, acts, on its way to the apex of the root, principally with its point, so that the root-canal, which, in section, is of an elongated conical shape, is more enlarged in its upper part, where it can least bear it than at its cervical end. It is, furthermore, a waste of force and an unsuitable distribution of it to give the canal such a form that the point of the pivot is given the same strength as its cervical end, when in reality the pressure at this end of the root is far greater than at the apex.

After making the pivot-tooth, it is fitted on

to the root by the use of transfer-paper (§ 321). "Thereby the places on the surface of the root touched by the tooth and the root-plate are marked blue, and if these points are afterwards ground down with an emery-wheel, and this procedure is repeated several times, the best possible fit of the tooth to the root-surface will be obtained."

§ 322. "Since the artificial tooth, by means of this trying in will always sit a little higher in the mouth than in the model, it is necessary in trying the tooth on the model to let it be about one half millimeter too long. It should also be noticed that the root-canal, soon before or during the trying in, must be burred out about one millimeter deeper. The trying in of the tooth is facilitated if the root-surface is beforehand concaved to a depth of two millimeters (with a wheelshaped bur with a conical point)."

The adjusting of the base of the tooth by means of transfer-paper, which according to my method is a seldom necessary expedient, is here made a necessity, although it is not only time-killing but also vague and not perfectly exact. On account of the circumstance that it is not possible to make even an isolated pivot-tooth after a model with perfectly accurate fit to the root, the use of this method in more complicated cases of bridge-work is doubtless still more unsuitable.

According to my method, the pivot-tooth is not made on a plaster model, but, after fitting in the mouth, both the casting and soldering are done at

once, thus making the fit to the root as perfect as can be desired.

As to the concaving of the cervical end of the root suggested as facilitating the trying in, which concavity is filled with cement when the tooth is put in place, I will simply refer to the criticism I made on a similar procedure in Stowell's method. I will here repeat that a loss of dentine substituted by cement at a place so severely exposed to the pressure of mastication, cannot help having an injurious effect on the stability both of the root and the tooth itself.

The pivot inserted into the root is, in fact, shortened these two millimeters which will rather become a kind of extension of the crown, unnecessarily augmenting the outer lever.

The further the point of the pivot is from its cervical support on the dentine, and the shorter the distance is between this point and the cutting-edge, the more solid the tooth will sit. By means of such a concave excision, however, this law is violated.

Comparison with Herbst's Method.

The great work "*Methoden und Neuerungen auf dem Gebiete der Zahnheilkunde*," in which Dr. Wilh. Herbst has collected his experiences from a practice of twenty-five years, contains in chapters XV. and XVI. some paragraphs which deserve to be reviewed here. The methods which are described in these chapters might, on superficial observation, appear to be somewhat related to some of the methods which

I use. I am, however, fully convinced that everyone, on more careful inspection and comparison, and especially by practical trials, can easily discover the considerable differences which exist between Dr. Herbst's tin-work and the work described by me, which is made of easily flowing, hard alloys.

It is not easy to get a clear idea of his complicated method from his rather unsystematic statement, which, on closer examination, is even found not to be very plain. I have therefore been obliged to avail myself of the assistance of a work by Dr. Fritz Holtbuer: "*Herb'sche Neuerungen für die Zahnärztlische Praxis,*" which is, on the whole, more connected and intelligible than the master's own book. There is no doubt that Dr. Herbst recognises as his the methods Dr. Holtbuer describes under his name, although contradictions between the two authors are not lacking.

I will here make a few comparisons between Herbst's and my method.

In making an impression, Herbst uses the well-known sticking-wax from Friese and Rohrschneider, which, before removal, he carefully cools with cold water, to keep it from bending or warping. In spite of this precaution, however, it seems that it sometimes happens that the impression cannot be got out in a perfect condition, but it is necessary to make an auxiliary impression with Stent's composition. (Herbst: p. 152).

The impression-composition made by me becomes so hard and strong in a few seconds in the ordinary temperature of the mouth without any special cooling,

that there is no danger of bending or warping, if the pivots are only parallel.

After the wax is cleaned out of the impression, Herbst uses a soldering-bit to melt the tin. In using this, the teeth are very easily cracked and are, as a rule, discoloured. Besides, the tin does not always run into all the depressions of the plaster impression, and he even recommends precautions for putting the cracked impression together again, — a very uncertain manipulation indeed.

According to my method, the alloy is caused to melt by means of successively heating the piece without the use of a soldering-bit. The whole is thus given an even degree of heat, so that the alloy can easily and with certainty be pressed down into every little depression, thus avoiding the above-mentioned disadvantages.

In substituting f. i. four upper incisors, when all the roots are intact, Holtbuer recommends (p. 59) such a peculiar procedure as to use either the two lateral or the two central roots as pivot-bearers, and to fill the two roots that are not used *with Chinese tooth-picks!* He says that as soon as they become damp, they fit admirably, a statement which is as true as it is wounding to one's sense for antiseptics. Furthermore, it does not seem to matter to the author which of the two roots supports the denture. Since all are equally good, it would be more wise to place each tooth on a separate pivot.

Some of the objections which can be made against tin as a basis for similar work are indirectly

recognized as just in many places in Dr. Herbst's work.

In order to keep the tin from wearing in the mouth, Dr. Herbst recommends plating with amalgam; thus the wear seems to be very considerable. Now if the pivot of the root has been exposed by wear, it is claimed that the amalgam will adhere so fast to the tin that the pivot will thereby be given new support.

The alloy used by me is, however, so little subject to wear that it does not need to be taken into consideration at all.

CHAPTER X.

Repairs.

The misfortunes to which a plateless denture is subject are principally of an accidental nature The deteriorization to which all artificial work in the mouth is exposed proceeds so slowly in plateless dentures that no special rules can be laid down for remedying it. In this kind of work, the deteriorization is closely related with the general health of the mouth, and cannot be materially retarded or remedied by means of mechanical operations. The conditions for the stability of a denture, its correct execution and careful fitting, cannot be lost if they have once been fulfilled, neither can they be supplied if they have originally been neglected. Hereby we win the great advantage of being sure that the work will last in case it was faultless from the beginning. It will, therefore, generally be possible to tell the patient what misfortunes *may* happen, with due respect to the greater or lesser probability of their happening, and at the same time it is possible to guarantee the patient against every surprise caused by hidden faults. Predictions in regard to lesions of a piece of work caused by outer violence, must

obviously be extremely vague. On the other hand, with respect to the lesions which can arise, for instance on account of bad articulations, it is possible to express a more definite opinion in regard to their eventual occurrence. I give below a list of these accidents and the methods which may be used for making necessary repairs.

In case a denture does not fall out entirely, lesions can effect the root, the pivot, or the porcelain facing.

Lesions of the Binding Element.

Already in the description of the insertion of the pivot-tooth, I have mentioned the danger to which a denture secured with cement is exposed, if it is hit so hard that the cement is crushed. If the work has loosened or entirely fallen out, the remains of the binding-element in the root-canal should be cleaned out and the denture reset. Dentures secured with guttapercha are so very seldom exposed to such misfortunes that one is tempted to believe that they have not been properly inserted when such an accident occurs.

Lesions of the Root.

A root may be fractured either throughout its whole length or partially. The cause of its fracture can be outer violence, f. i. a stroke or a fall, or it may be brought about by too strong biting. The

cause plays no essential part in the prognosis; the nature of the fracture is here the only decisive element.

If the fragment is little, it is taken away, after which it is ascertained whether the remaining piece is sufficiently strong to fulfil the former function of the root.

Different methods have been suggested for securing the fragments of a root split throughout its whole or nearly its whole length. I regard a gold or platinum cap to be surest means. The objections which can generally arise against the use of a cap or collar around the root, disappear before the serious nature of this dilemma. The cap is made in the usual manner. With a suitable instrument the sides of the cervical end of the root are made parallel, a strip of thin gold or platinum plate is fitted to the margin, its ends are soldered together, a cover of metal is fitted, soldered on, and perforated, after which the cap is secured by cement. First after the fragments have been fixed in this manner, the tooth is inserted. In such a case, a pivot-tooth with a collar soldered fast to it should not be used, since by inserting both pivot and collar at the same time, there is danger of pressing the fragments apart. I was once obliged to put such a cap on the root of an upper central incisor with a deep fracture, and then let this root and one more act as supports for a denture of five teeth, a function which they still fulfil satisfactorily for the third year. If it proves to be impossible to unite the fragments of a fractured root

by means of the above-described cap or any other means, there is nothing for it but extraction. In case this misfortune happens to an isolated root, which participates in the support of a larger denture, it is frequently rather difficult to unite it. In smaller work with more possibilities for mending the fracture, such a compelled extraction is nowhere near so threatening. Fortunately this kind of accident occurs so very seldom that one should not for that reason be tempted to submit to the unpleasantness connected with the use of collars around all roots bearing pivot-teeth.

Lesions of the Pivot.

Lesion of the pivot occurs very seldom, and almost always as a result of a careless execution of the work. It consists in the bending of the pivot so that the crown is driven outwards or is even broken. It is obvious that such an accident could not happen if the pivot had been made of sufficiently hard material, hard-drawn iridio-platinum wire, or had been thick enough, and if the articulation had been carefully fitted. To remedy this injury, the work must be taken out, or the pivot must be drilled out, and a new pivot inserted. As to the execution of these manipulations, I must refer to the next division of this chapter.

Lesions of the Porcelain Facing.

The accidents which may be met with by the porcelain facing, and which generally consist in its being crushed or its pins breaking off, occur, I am sorry to say, more frequently than the other misfortunes, wherefore, I generally prepair the patient by saying that such accidents may happen. The dentist is generally not to blame for such accidents. The porcelain teeth in the market are by no means sufficiently strong to withstand all the pressure which can be brought to bear on them in chewing. It is impossible to guard against the crushing of the porcelain crown, even if all known precautions are used. After holding for several years, it is well known that a porcelain crown can quite unexpectedly break, as a result of a momentary strain, or its pins may break off close to the porcelain. Both of these lesions are treated in the same manner.

For repairing a crushed porcelain facing, the work should preferably be taken out, no matter whether it consists of a single pivot-toot or of several connected teeth. This is done without difficulty in case it is a denture secured by guttapercha. A piece of metal, f. i. the handle of a file or the jaws of a discarded pair of forceps, is heated enough for the heat to be conducted into the pivot and soften up the guttapercha.

After enough of the work thus removed has been filed off to make it possible to try in a new

porcelain crown ground to fit the root, my impression-composition is burnt fast to the remaining metal. The somewhat warmed piece of work is again pushed up into place, and the tooth is fastened to the impression composition. When the work is again taken out, it is invested in plaster, is freed from impression-composition in the usual manner, after which the casting is done, care being taken that the temperature is not greater than is needed for melting the little cube of metal.

Dentures set in cement are, of course, much more difficult to remove whole, and sometimes this is quite impossible. If one can succeed in turning the pivot, if only one degree, the victory is won. If this is not successful, the work must be taken to pieces. Some of the metal around the protruding end of the pivot is removed, so as to expose the point of its entrance into the root-canal. With a very small rose-bur a passage is made around the pivot as high up as possible, and then an attempt is again made to turn the pivot. It is also possible to take off the protruding end and with a trepan-bur try to liberate the pivot somewhat. If this is not successful, the pivot must be drilled out in the following manner: —

By means of a point-cutting bur, f. i. an ordinary revelation-bur, we work slowly up the pivot. It is sometimes difficult to get the bur started, but if the pivot-tooth is ground smooth on a level with the cervical surface of the root, this is frequently facilitated. On coming higher up in the canal, one

is guided by the shining spot caused by the point of the bur. It is of great importance that this shining spot is kept in the centre of the pivot. On account of the caution which must be observed, this operation is a slow one, but there is no special, intimidating danger of failure. With patience and sharp burs there is a good prospect of success.

If the work is also secured by a collar, it is loosened by making an incision in it with a bur or little grinding-wheel. The work is now done over, using such old parts as are still utilizable.

Repairs of a Denture without removing it.

Fortunately enough, it is generally possible to substitute a porcelain facing with considerable correctness without removing the denture. The above descriptions of troublesome removal and partial remaking of the denture only have reference to very bad cases. Otherwise a crushed porcelain tooth is substituted in the following simple manner. Remaining fragments of the porcelain crown are removed, the two pivot-heads are burred away, and from their place two parallel canals are bored clear though the metal. The pivots of the newly chosen crown are passed through these canals, the cervical margin of the crown is ground to fit the root or the gums, and the whole palatinal surface of the crown is made to fit closely to the metal. In order to do this fine grinding most accurately, some articulation-paste may

be used. The pivots of the crown are then made somewhat rough and pressed further in, and it is ascertained whether their ends protrude so far in a palatinal direction that they can be strongly riveted. If this is not the case, they must be spliced by soldering on a piece. In order to do this properly, the pivots are flattened up to about a millimeter from the ends; two pins from a discarded tooth are flattened in the same manner, and then the crown with the pivots in the proper position are either invested in plaster or fastened in a vice on a piece of charcoal, and are soldered with gold. The prolonged pivots are filed and fitted, their protruding ends are made so thin that, after insertion, they can be bent down into burred-out depressions on the back of the metal without too strong pressure. Then the crown is inserted with soft, mixed cement on the pivots and the back of the crown, after which the flattened ends of the pivots are immediately bent by means of a polishing-steel, or the like, and are carefully hammered down or, if possible, riveted with an automatic filling-hammer In order to be still more sure, a sharp, dovetailed excision can be made with a diamond wheel straight across the back of the porcelain crown below the pivots and in the metal just opposite this incision, a slightly undercut cavity. If these two excisions are filled with cement on inserting the work, its stability will be considerably increased.

This way of securing a porcelain crown may, at first thought, seem to be temporary. I have,

however, known crowns thus secured to do service for several years.

On two occasions, the crown has been crushed again, which shows that the connection between the tooth and the crown could stand a heavier pressure than the porcelain tooth itself.

If, for instance, on account of bad articulation, the metal behind the crown is so thin that it cannot admit of two canals being bored in it, without being to much weakened, the following method may be resorted to: Enough of the metal is removed to allow the crown to be ground and its pins, bent at the ends but not prolonged, to have a sure position. A small, dampened napkin is placed so as to protect the lip and the gums. Then the surface of the fracture is dampened with soldering-acid, and a little piece of metal is laid on, which is melted by hurriedly touching it with a Paquelin termocauter or a strong galvanocauter. The surface is again dampened with soldering-acid, a new piece of metal is melted on, and so on till the contour has been fully renewed, after which the articulation is tried, and the surface is polished. This operation should not be resorted to, however, except in cases of necessity, since it requires such great accuracy in order to give a perfect result.

I have not, as yet, been obliged to make any other kind of repairs on the metal. It never loosens from the pivot and never wears so much that any addition needs to be made to it. If the reinforcement of platinum wire above described is never

omitted in large work, there is no danger that these pieces, even if they are subjected to very heavy pressure in chewing, will be bent or crushed.

I have taken up considerable space in describing the methods for remedying lesions in this kind of work, and I have done this, not so much because such misfortunes occur so often, but rather because they are all the more liable to perplex the operator just on account of their occurring so seldom. It is one thing to have been exposed to a misfortune, and another to be able "to get out of the mess." The more at home one is in the circumstances which can threaten the stability of a piece of work, the more capable one is to avoid them. Likewise, the significance of an accident is greatly reduced if one only knows how to make things right again. If the operator has been able skillfully to put into practice the doctrines in regard to the execution of the work, it will seldom be necessary to look up the chapter on repairs, but when they are necessary, I hope these details in regard to repairs will not be considered superfluous.